
Electronic Thesis and Dissertation Repository

9-2-2015 12:00 AM

Effects of Acetabular Positioning in Total Hip Arthroplasty

Prateek Goyal, *The University of Western Ontario*

Supervisor: Dr. James Howard, *The University of Western Ontario*

Joint Supervisor: Dr. Brent Lanting, *The University of Western Ontario*

Joint Supervisor: Dr. Matthew Teeter, *The University of Western Ontario*

A thesis submitted in partial fulfillment of the requirements for the Master of Science degree in Surgery

© Prateek Goyal 2015

Follow this and additional works at: <https://ir.lib.uwo.ca/etd>



Part of the [Orthopedics Commons](#), and the [Surgery Commons](#)

Recommended Citation

Goyal, Prateek, "Effects of Acetabular Positioning in Total Hip Arthroplasty" (2015). *Electronic Thesis and Dissertation Repository*. 3273.

<https://ir.lib.uwo.ca/etd/3273>

This Dissertation/Thesis is brought to you for free and open access by Scholarship@Western. It has been accepted for inclusion in Electronic Thesis and Dissertation Repository by an authorized administrator of Scholarship@Western. For more information, please contact wlsadmin@uwo.ca.

EFFECTS OF ACETABULAR POSITIONING IN TOTAL HIP ARTHROPLASTY

(Thesis format: Integrated Article)

by

Prateek Goyal

Graduate Program in Surgery

A thesis submitted in partial fulfillment
of the requirements for the degree of
Master of Surgery

The School of Graduate and Postdoctoral Studies
The University of Western Ontario
London, Ontario, Canada

© Prateek Goyal 2015

Abstract

Positioning of the acetabular component is critical to a successful total hip arthroplasty. This dissertation retrospectively examines 1,010 hips to study the effect of acetabular position on patient reported functional outcomes, which is not currently elucidated in literature. As the modified Hardinge approach is one of the most common surgical approaches used for total hip arthroplasty, we studied the same cohort to ascertain the accuracy of cup placement when using this approach. Moreover, the effect of acetabular position on polyethylene wear rates is prospectively examined in 43 hips with highly crosslinked polyethylene using radiostereometric analysis.

Absolute and relative acetabular position was found to be weakly correlated with functional outcomes but the results are not clinically significant. Furthermore, cup position did not correlate with polyethylene wear in highly crosslinked polyethylene. The modified Hardinge approach was found to be 43.6% accurate in achieving the intended combined anteversion and inclination angle.

While specific intraoperative targets for acetabular position may be important for hip stability, there may be no change in patient outcomes and polyethylene wear.

Keywords

Acetabular Positioning, Total Hip Arthroplasty, Radiostereometric Analysis, Anteversion, Inclination Angle, Polyethylene Wear

Co-Authorship Statement

This dissertation contains original manuscripts that are intended for submission to peer-reviewed journals. The individual contributions of the authors to each manuscript are stated below.

Chapter 2 is an original manuscript co-authored by Prateek Goyal, Adrian Lau, Matthew Teeter, James L. Howard and Brent A. Lanting. Chapter 3 is also an original manuscript co-authored by Prateek Goyal, Adrian Lau, Matthew Teeter, Brent A. Lanting and James L. Howard. For chapters 2 and 3, I participated in designing the study, collected the data, analyzed the results, and wrote the manuscript text. Dr. Adrian Lau assisted in the data collection required for both of these chapters. He was involved in the radiographic analysis of the acetabular component. He also contributed to the project through verification of previously tabulated patient data. Dr. Matthew Teeter, Dr. James Howard and Dr. Brent Lanting were instrumental in the development of ideas/design for the project, clinical assessment of patients, data interpretation and manuscript preparation.

Chapter 4 is an original manuscript co-authored by Prateek Goyal, Xunhua Yuan, Matthew Teeter, James L. Howard and Brent A. Lanting. I participated in designing the study, recruiting patients, acquiring the required patient radiographs for the study, analyzing the data and wrote the manuscript text. Dr. Xunhua Yuan contributed to this project as an expert on radiostereometric analysis. He dedicated numerous hours to this project by aiding in acquisition of radiographs and accompanying polyethylene wear measurements for those radiographs. Dr. Matthew Teeter, Dr. James Howard and Dr. Brent Lanting were once again very helpful in the development of ideas/design for the project, clinical assessment of patients, data interpretation and manuscript preparation.

Acknowledgments

To my supervisors (Drs. Matthew Teeter, Brent Lanting and James Howard) – thank you spending numerous hours meeting with me and providing invaluable feedback. I would like to express my gratitude towards all the time you spent teaching me about arthroplasty and the intricacies of research methodology. Each one of you is a great mentor to me and I hope to continue relying on you for your useful advice. Dr. Lanting and Dr. Howard - you have both demonstrated to me that a research career and a busy clinical practice can be simultaneously maintained if proper motivation exists. You are all an inspiration to me and I will look up to you for the rest of my life. I hope to receive continued support from you as you have so generously provided so far.

To Paril Suthar – thank you for your continued patience and willingness to go out of your way to help with the study whenever my clinical duties mandated my presence elsewhere away from the clinic and my research obligations.

To Drs. Steven MacDonald, James McAuley, Edward Vasarhelyi, Richard McCalden and Douglas Naudie – thank you for allowing me to use the data on your patients to examine it retrospectively for the purposes of this dissertation.

To Dave Reese – thank you for performing the necessary radiography required for the study in my absence whenever I was away due to my clinical duties. Thank you for assessing our x-ray setup and suggesting improvements for acquiring the best radiographs. I also appreciate your work on the algorithms required for processing the acquired radiographs to improve the quality of the image.

To the orthopaedic clinic staff – thank you for accommodating the research patients in one of the busiest clinics in the hospital. I appreciate your patience and support.

Table of Contents

| | |
|---|------|
| Abstract | ii |
| Co-Authorship Statement..... | iii |
| Acknowledgments..... | iv |
| Table of Contents | v |
| List of Tables | viii |
| List of Figures | x |
| List of Appendices | xi |
| List of Abbreviations | xii |
| Chapter 1 | 1 |
| 1 Introduction..... | 1 |
| 1.1 Hip Anatomy..... | 1 |
| 1.2 Osteoarthritis..... | 3 |
| 1.3 Total Hip Arthroplasty..... | 4 |
| 1.4 Surgical Technique | 6 |
| 1.5 Radiographic Imaging of the Hip | 9 |
| 1.6 Importance of Acetabular Component Positioning..... | 15 |
| 1.7 Research Objectives..... | 18 |
| 1.8 References..... | 20 |
| Chapter 2..... | 24 |
| 2 Accuracy of the Modified Hardinge Approach in Acetabular Positioning..... | 24 |
| 2.1 Introduction..... | 24 |
| 2.2 Methods..... | 25 |
| 2.3 Results..... | 27 |

| | |
|--|----|
| 2.4 Discussion..... | 31 |
| 2.5 References..... | 35 |
| Chapter 3..... | 38 |
| 3 Effect of Acetabular Component Positioning on Functional Levels in Primary Total Hip Arthroplasty..... | 38 |
| 3.1 Introduction..... | 38 |
| 3.2 Methods..... | 39 |
| 3.3 Results..... | 42 |
| 3.4 Discussion..... | 47 |
| 3.5 References..... | 51 |
| Chapter 4..... | 53 |
| 4 Effect of Acetabular Position on Polyethylene Liner Wear using a Novel Radiostereometric Analysis Technique..... | 53 |
| 4.1 Introduction..... | 53 |
| 4.2 Methods..... | 55 |
| 4.3 Results..... | 58 |
| 4.4 Discussion..... | 62 |
| 4.5 References..... | 65 |
| Chapter 5..... | 68 |
| 5 Discussion..... | 68 |
| 5.1 Future Directions..... | 70 |
| 5.2 References..... | 72 |
| Appendix A: University of California Los Angeles Activity Score..... | 74 |
| Appendix B: Ethics Approval..... | 75 |
| Appendix C: Letter of Information and Consent Form..... | 77 |
| Appendix D: Permissions for Copyrighted Material..... | 83 |

Curriculum Vitae 84

List of Tables

| | |
|---|----|
| Table 1-1: Review of previous studies attempting to define ideal inclination and anteversion angles..... | 17 |
| Table 2-1: Post-operative outcome scores of patients who underwent the modified Hardinge approach for their total hip arthroplasty..... | 27 |
| Table 2-2: Comparison of cup positioning accuracy between different approaches as demonstrated in previous studies..... | 28 |
| Table 2-3: Distribution of the hips within described range of anteversion and inclination angle..... | 29 |
| Table 2-4: Univariate analysis of various factors for combined acetabular cup position within the Lewinnek's "safe zone"..... | 30 |
| Table 2-5: Multivariate analysis of factors for predicting accurate component position within the Lewinnek's zone (n=958)..... | 31 |
| Table 3-1: Functional Outcome scores showing comparison of mean pre-operative functional scores and post-operative outcome scores..... | 44 |
| Table 3-2: Correlation between functional outcome scores and anteversion..... | 44 |
| Table 3-3: Correlation between functional outcome scores and inclination angle..... | 45 |
| Table 3-4: Correlation between functional outcome scores and anterior overhang..... | 45 |
| Table 3-5: Correlation between functional outcome scores and lateral overhang..... | 46 |
| Table 3-6: Comparison of mean functional outcome scores between patients who have lateral overhang and patients who have no lateral overhang..... | 46 |
| Table 3-7: Comparison of mean functional outcome scores between patients who have anterior overhang and patients who have no anterior overhang..... | 47 |

| | |
|--|----|
| Table 3-8: Comparison of mean functional outcome scores between patients who had the cup within the Lewinnek’s “safe zone” and outside the Lewinnek’s “safe zone”..... | 47 |
| Table 4-1: Demographics of the patient population | 56 |
| Table 4-2: Mean pre-operative and post-operative patient reported functional outcome data..... | 62 |

List of Figures

| | |
|---|----|
| Figure 1-1: Components of a metal-on-polyethylene total hip arthroplasty..... | 5 |
| Figure 1-2: Lateral (Hardinge) approach to the hip..... | 8 |
| Figure 1-3: Radiographic views for evaluation of a total hip arthroplasty | 10 |
| Figure 1-4: Measurement of inclination angle..... | 12 |
| Figure 1-5: Measurement of anteversion angle using the Woo and Morrey Method..... | 12 |
| Figure 1-6: Measurement of anteversion angle using the Ischiolateral method. | 13 |
| Figure 1-7: Lateral view of a THA with implantation of tantalum marker beads. | 14 |
| Figure 1-8: Mechanical alignment guide. | 16 |
| Figure 2-1: A scatter-diagram summary of the orientation of the acetabular components in the study population..... | 28 |
| Figure 2-2: A temporal view of inclination angles of all hips from 2003 to 2011. | 33 |
| Figure 3-1: Measurement of Lateral Overhang. | 41 |
| Figure 3-2: Measurement of Anterior Overhang. | 41 |
| Figure 3-3: Cups within the Lewinnek’s “safe zone”. | 43 |
| Figure 4-1: RSA setup with setup to acquire AP and lateral radiographs. | 57 |
| Figure 4-2: Graphic representation of the position of acetabular components..... | 59 |
| Figure 4-3: Graphic representation of the acetabular anteversion and wear rate. | 60 |
| Figure 4-4: Graphic representation of the acetabular inclination angle and wear rate. | 61 |

List of Appendices

| | |
|--|----|
| Appendix A: Functional Outcome Scores | 74 |
| Appendix B: Ethics Approval | 75 |
| Appendix C: Letter of Information and Consent Form | 77 |
| Appendix D: Permissions for Copyrighted Material | 83 |

List of Abbreviations

AP – Anteroposterior

BMI – Body Mass Index

CT – Computed Tomography

HHS – Harris Hip Score

MCID – Minimal Clinically Important Difference

NSAIDs – Non-steroidal anti-inflammatory Drugs

OA – Osteoarthritis

PACS – Picture Archiving and Communications System

RSA – Radiostereometric Analysis

SF-12 – Short Form - 12

THA – Total Hip Arthroplasty

WOMAC – Western Ontario and McMaster Universities Osteoarthritis Index

UCLA – University of California Los Angeles Activity Score

Chapter 1

1 Introduction

1.1 Hip Anatomy

The normal native hip is a ball-and-socket joint that allows a wide range of motion. The acetabulum and the femoral head are the osseous constituents of a native hip.

Transmission of forces up to five times the body weight occur across this joint during activities such as running and climbing stairs [1]. External forces and moments are typically balanced by a series of forces and moments generated internally by muscle contraction, soft tissue tension and articular reaction forces [1].

The acetabulum forms from the coalescence of three ossification centers (collectively called the 'triradiate cartilage'): ilium, pubis and ischium. The triradiate cartilage gives rise to the anterior wall, posterior wall and the dome of the acetabulum. On the most lateral aspect, it forms a circumferential lip of hyaline cartilage centrally and fibrocartilage on the periphery [1]. During maturation, this cartilaginous cup gains its final shape, concentrically covering 170 degrees of the femoral head [2]. The triradiate cartilage subsequently closes between ages 14 to 16 [1].

The acetabulum has an average diameter of 52 ± 4 mm [1]. Men tend to have larger diameters compared to women. Average anteversion of the native acetabulum measures 16 to 21 degrees with an average inclination of 48 degrees [1]. Men tend to have less anteversion than females [1]. The transverse acetabular ligament, located inferiorly, connects the anterior and posterior walls of the acetabulum forming a tension band against deformation of the wall from force transmission [1]. The acetabulum is supported by two strong columns of bone. The anterior and posterior columns connect the acetabulum to the pelvis and allow force transmission between the trunk and the lower extremity [1].

The cartilage is normally deficient medially and inferiorly in the acetabulum. The cartilage of the acetabulum, therefore, forms a horseshoe with the acetabular fossa in the

center [2]. The acetabular fossa is a central cavity containing the ligamentum teres and a fat pad called pulvinar. The ligamentum teres connects the acetabulum to the fovea of the femoral head. It has been hypothesized to be a pain generator and instrumental in synovial fluid distribution and stability [1]. The labrum, which arises from the limbus, is a ring of connective tissue surrounding the outer edge of the acetabulum [1]. The labrum consists of three distinct layers, all formed from collagen. Its role is to deepen the acetabulum, which aids in dissipation of load by increasing the contact area [2]. Inferiorly, the labrum cannot be distinguished from the transverse acetabular ligament [1].

The proximal femur consists of the femoral head, femoral neck, greater trochanter and lesser trochanter. The femoral neck has an anteversion of 10.5 ± 9.22 degrees [1]. The normal neck-shaft angle of the femur measures 125 degrees [2]. The lesser trochanter is retroverted 31.5 degrees [2]. The gluteus medius and gluteus minimus attach to the greater trochanter. The lesser trochanter serves as an attachment to the iliopsoas tendon. The femoral head is spherical in shape with a central depression known as the fovea. The ligamentum teres attaches to the fovea.

The hip capsule is a fibrous structure surrounding the hip joint [1]. Its role is to provide stability to the joint throughout a wide range of motion. The capsule also carries the blood supply to the joint [2]. It originates on the lateral aspect of the acetabulum and inserts on the intertrochanteric region of the proximal femur. The hip capsule consists of longitudinal fibers of iliofemoral, ischiofemoral, and pubofemoral ligaments [2]. The inner layer of the hip capsule, however, is formed by circumferential zona orbicularis fibers [2].

The hip joint is surrounded by 27 muscles crossing the hemipelvis, which are instrumental in dynamic stability of the hip and aid in muscular balance [2]. The muscles adjacent to the hip include anteriorly situated hip flexors and posteriorly located hip extensors. The abductors, including gluteus medius, gluteus minimus and *tensor fascia lata*, are located on the lateral aspect of the joint and adductors in the medial

compartment. External rotators and internal rotators also constitute the muscle layers surrounding the hip.

1.2 Osteoarthritis

Osteoarthritis (OA) is a progressive degenerative disease affecting the articular cartilage of a joint. It begins as a result of overloading of the articular cartilage. The failure of chondrocytes to maintain articular cartilage after injury results in net destruction of the cartilage. The imbalance in breakdown and repair of joint tissues in OA is due to activation of inflammatory mediators, matrix components and mechanical stress. Characteristic alterations to the cartilaginous part of the joint include an increase in water content and changes in proteoglycan concentration. The inflammatory response from various cells also leads to collagen destruction, synovial hypertrophy and bone remodeling [3].

The etiology of OA remains multifactorial and has been described in the context of excessive mechanical stress applied to susceptible patients [3]. Risk factors include genetic inheritance, obesity, age, ethnicity, nutritional factors and female gender. Patients with joint alterations in the form of the mechanical alignment, periarticular muscle weakness, and intra-articular structural pathology may accelerate disease progression.

OA is one of the most commonly diagnosed diseases by family physicians. It is anticipated that the prevalence of OA will double by 2020 as a result of an aging population and an increase in obesity [4]. In addition to disability, OA represents a substantial burden to society from an economic standpoint. In Ontario, an increase in healthcare costs by 2-3 times is seen in patients suffering from OA. Quality of life is deemed 10-25 percent lower in individuals diagnosed with OA when compared to control subjects [5].

OA has a predilection for the large lower extremity joints such as the hip and knee. Pain is the predominant symptom of OA with patients typically complaining of pain that worsens with activity. Stiffness is also a common symptom of OA affecting active and

passive ranges of motion of the affected joint. Crepitus and gait disturbances are also described by patients suffering from OA.

Unfortunately, a cure for OA still remains elusive and current management focuses on addressing pain, stiffness, and functional limitations. Non-operative modalities are the first line treatment of OA. These conservative measures work by offloading the affected joint. Rest and activity modification are general recommendations for patients suffering with OA. Weight loss in obese patients has been shown to be an effective treatment option. Braces and splints can support the affected joint, which may relieve symptoms. Pharmacologic treatments in the form of non-steroidal anti-inflammatory drugs (NSAIDs), Tylenol and opioids are mainstay treatment for OA. Local injections into the affected joints including viscosupplementation and corticosteroids have also been advocated. These modalities can provide pain relief to patients in early stages of OA. As the disease progress, however, patients are often increasingly limited in their activities as a result of the debilitating pain and stiffness. Joint arthroplasty is indicated for such patients to alleviate symptoms.

1.3 Total Hip Arthroplasty

In medical nomenclature, joint reconstruction procedures are termed as “arthroplasty”. *Arthr(o)-* refers to the procedure as it is “related to a joint” while *-plasty* from Greek origin means “to form”. Arthroplasty procedures can be performed on any joint in the body and entails an operative reconstruction of the joint. Examples of arthroplasty include resection arthroplasty (excision of articulating surfaces), interposition arthroplasty (insertion of a substance such as fascia, dermis, cartilage between articulating surfaces of a joint) and total joint arthroplasty. A total joint arthroplasty refers to non-biologic replacement of articulating surfaces of a joint.

The most common surgical procedure for hip OA is total hip arthroplasty (THA). Wiles is known to have created the first prosthetic total hip replacement in 1938. Early designs suffered from poor materials, mechanical failure and design problems. Sir John Charnley, a British orthopaedic surgeon, subsequently developed the concept of low-friction arthroplasty by suggesting the use of acrylic cement to affix components, polyethylene as

a bearing surface, and low friction torque arthroplasty [6]. Since the introduction of low-friction arthroplasty, advances have been made in metallurgy, tribology, and surgical techniques of THA. For example, developments in cementing techniques have evolved considerably from simple finger packing of the cement. Modern cementing approach involves the use of distal centralizers, pulse lavage of the femoral canal, and sustained pressurization of cement to optimize inter-digitation of the cement and bone to create a uniform cement mantle for the THA prosthesis [6]. Furthermore, the conventional polyethylene designs have been modified with the use of gamma radiation and ultrahigh-molecular-weight polyethylene to induce crosslinking [6]. The ultrahigh molecular weight crosslinked polyethylene has been shown to have improved wear characteristics compared to conventional polyethylene [7]. Other modern improvements in metallurgy, tribology, surgical techniques and overall success of THA has led this procedure to be named the “Operation of the 20th Century” in 2007 [6].

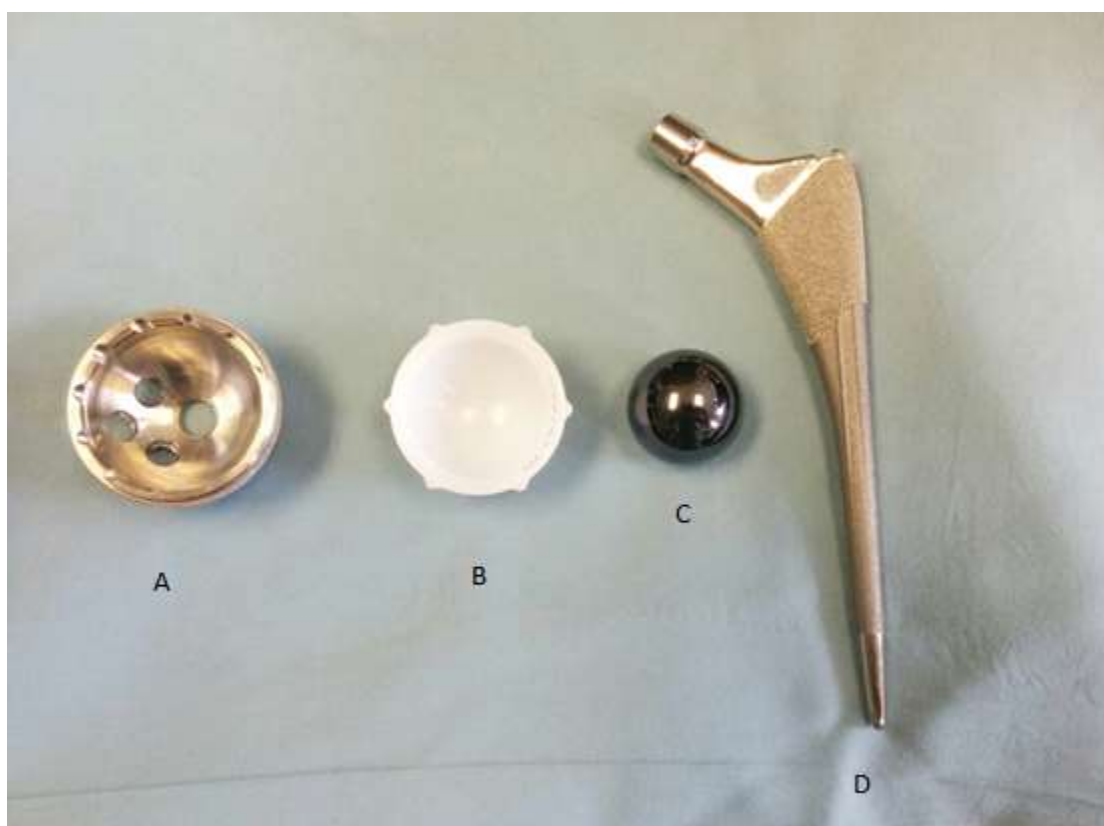

Figure 1-1: Components of a metal-on-polyethylene total hip arthroplasty.
A) Acetabular component B) Polyethylene liner C) Femoral Head D) Femoral stem.

A THA consists of a femoral component, acetabular component and a bearing surface. Current THA implants offer modularity whereby the femoral head is a separate component from the femoral stem, while the acetabular liner can be fitted into a separate acetabular shell (Figure 1-1). Different implant designs allow fixation of the acetabular shell and femoral stem to be performed with or without the use of cement. The technique to affix components without the use of cement relies initially on an interference fit, while osseous integration of the implant into host bone provides eventual fixation after the initial phase. Although many bearing surfaces exist, the most common bearing surface used in Canada is a metal head on highly cross-linked polyethylene liner, i.e. metal-on-polyethylene articulation [8].

The rate of THA being performed in Canada is increasing on a yearly basis [8]. THA has been a very successful procedure in addressing pain and functional limitations of patients suffering with OA [9]. Patients report significant improvements in their physical health in the post-operative period, especially within the first six months. Pain scores have been shown to improve the most within a short period of time [9]. Physical function has been demonstrated to improve significantly after THA when compared to pre-operative functioning [9]. Long-term studies have shown that these improvements are not short-lived. Modest improvements have also been reported by patients in their mental health and social functioning after undergoing a total hip arthroplasty [9].

1.4 Surgical Technique

A variety of surgical approaches exist in order to gain access to the femur and acetabulum to perform a THA. The anterior approach (Heuter or Smith-Peterson approach), posterior approach (Southern-Moore approach) and direct lateral approach (Hardinge approach) are commonly used by arthroplasty surgeons. Although each approach has its own advantages and disadvantages, the most common approach used at London Health Sciences Centre is the modified Hardinge approach.

Hardinge originally described the lateral approach to be performed with the patient in a supine position (Figure 1-2). In order to obtain better visualization, the Hardinge approach was modified with the patient in a lateral decubitus position with the patient

lying on the unaffected side. The modified Hardinge approach offers good visualization of the acetabulum, with low rates of prosthetic dislocation of the head from the acetabular component. As this approach violates abductor musculature and has an increased risk for superior gluteal nerve injury [10], it is associated with an increased risk for a post-operative limp.

The modified Hardinge uses a lateral skin incision centered over the greater trochanter. After subcutaneous dissection, the iliotibial band (arising from the tendons of *tensor fasciae lata* and gluteus maximus) is identified. The iliotibial band is split in line with the skin incision to reveal the gluteus medius musculature overlying the anterolateral aspect of the femur. The gluteus medius is subsequently split to expose the tendinous portion of the gluteus minimus overlying the femoral neck. The tendon of the gluteus minimus along with the hip capsule is split in line with the femoral neck. The tendon of gluteus medius and minimus are then reflected off the femur anteriorly followed by proximal fibers of the vastus lateralis. The femoral head is subsequently dislocated. A femoral neck osteotomy is performed, which improves the exposure of the acetabulum.

After carefully placing the retractors around the acetabulum, peri-articular structures such as the labrum and osteophytes are removed. Sequential reaming is performed to allow an interference fit between the acetabular bone and the acetabular component. After determining the correct acetabular position, the acetabular component is impacted into the reamed bony bed if a cementless technique is utilized. In the case of a metal-on-polyethylene THA, the polyethylene liner is subsequently locked into the acetabular component.

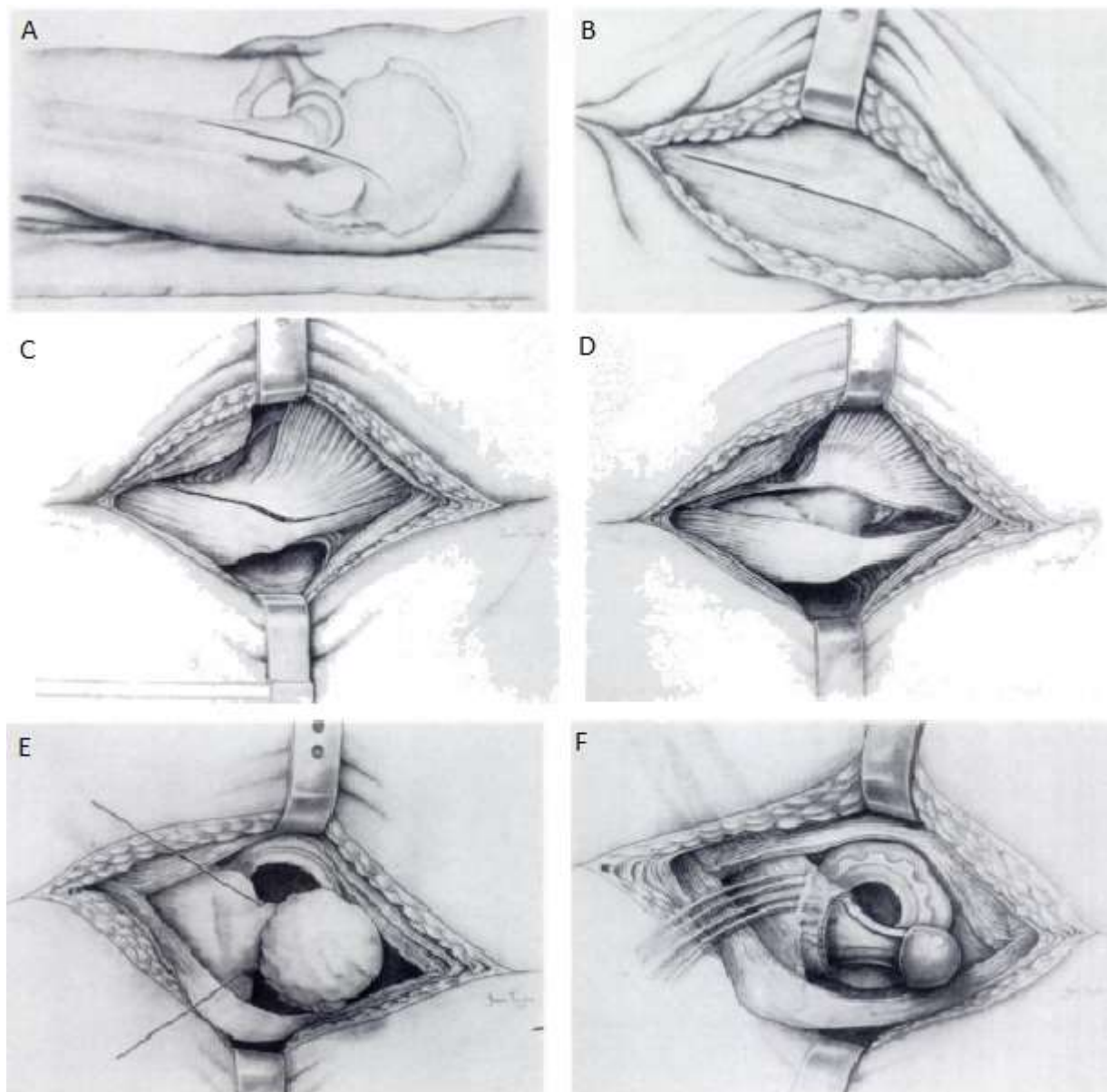


Figure 1-2: Lateral (Hardinge) approach to the hip.

A) Skin incision is centered on the greater trochanter. B) Iliotibial band is divided C) Gluteal medius is split with some tendinous attachment left behind on the greater trochanter to aid in closure D) Femoral neck is exposed after dissection through gluteus minimus and capsule with elevation of muscular flap off the anterior aspect of the proximal femur. E) Surgical hip dislocation is carried out. F) Final implantation of THA components. (Reproduced with permission and copyright © of the British Editorial Society of Bone and Joint Surgery from Hardinge, K. J Bone Joint Surg Br 1982; 64-B(1): 17-19)

The femoral canal is identified within the femur and sequentially prepared using broaches. The final broach is determined based on axial and rotational stability of the broach within the femoral canal. In a cementless technique, the femoral stem is subsequently impacted into the femoral canal. Alternatively, a femoral stem may be cemented into the femoral canal using polymethylmethacrylate based on surgeon's preference. The femoral head is then impacted onto the femoral stem.

A series of trialing processes occur between the steps described above to determine the adequate soft tissue tensioning, leg length, femoral offset and stability. A careful closure of all tissue layers is carried out at the end of implantation of the components.

1.5 Radiographic Imaging of the Hip

Radiography is the primary diagnostic imaging tool to assess for diseases affecting the hip. It is also an effective tool in surveillance and subsequent treatment of diseases. Radiographs are a cost-effective tool exposing the patient only to a small amount of radiation. Radiographs can be performed with ease by technicians and with minimal discomfort to the patient. The most common radiographic views obtained consist of an anteroposterior (AP) view of the pelvis and a cross-table lateral view of the affected hip (Figure 1-3). An AP view of the pelvis (as opposed to solely the hip under examination) is usually performed as it allows for evaluation of the contralateral hip and provides anatomic details necessary for an operative intervention.

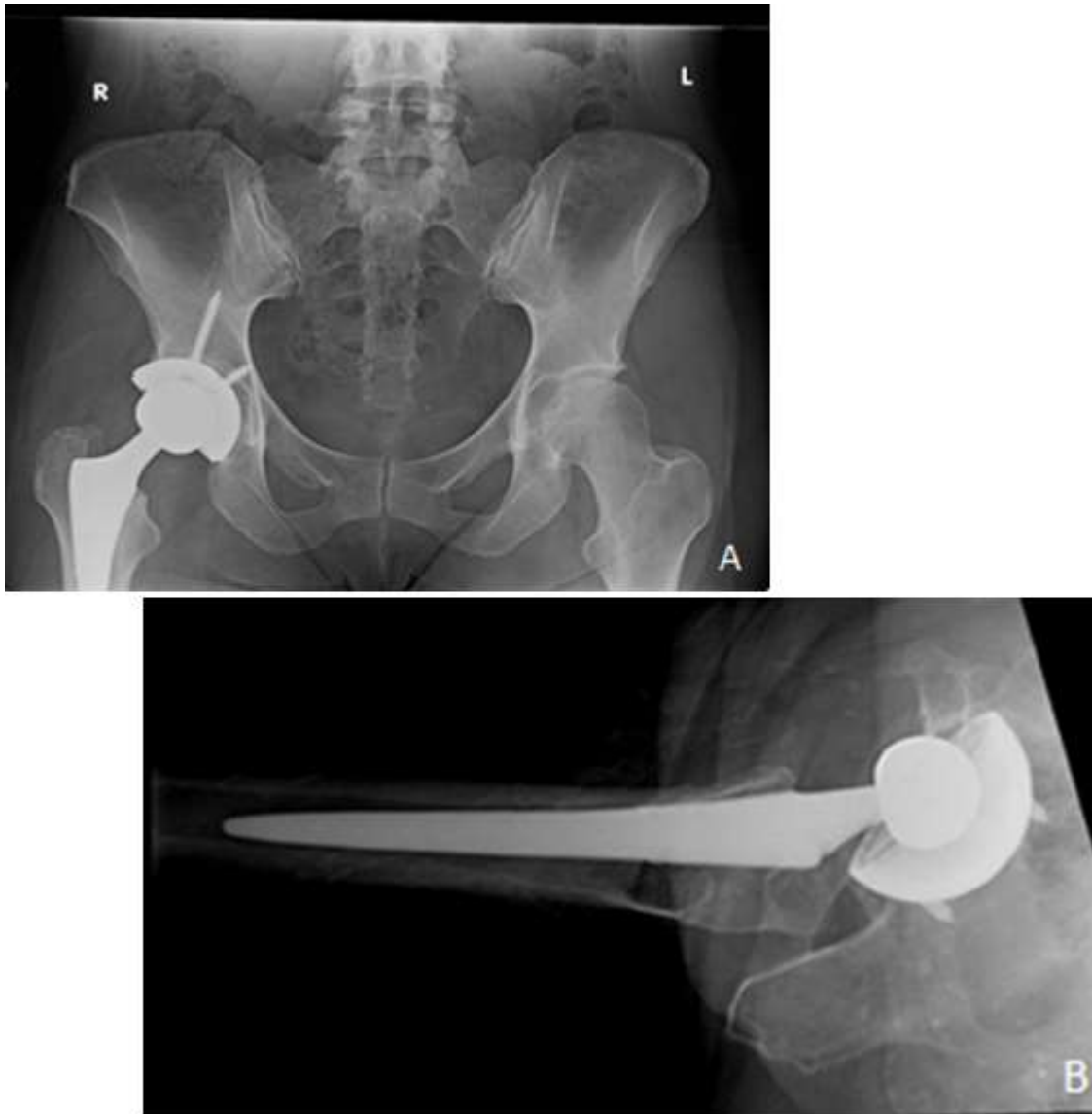

Figure 1-3: Radiographic views for evaluation of a total hip arthroplasty
 A) Anteroposterior view B) Cross-table Lateral view

Radiographic signs of OA include joint space narrowing reflecting loss of cartilage, formation of osteophytes (reactive bone), sclerosis and cyst formation in the subchondral bone (bone underlying the cartilage). Joint space narrowing is the most sensitive sign of OA and can be used as a proxy for progression of the disease. Kellgren and Lawrence developed a classification system divided into five types to describe the severity of OA in a joint based on radiographs [11]. Type 0 shows no signs of OA, while type 1 has small osteophytic lipping with no joint space narrowing. Type 2 has been described to have definite osteophytes with possible narrowing of joint surface. Type 3 shows definite joint

space narrowing with moderate multiple osteophytes. Type 4 have marked joint space narrowing with subchondral sclerosis along with deformity of bone contour and large osteophytes.

Radiographs remain the primary skeletal imaging modality after THA for post-operative evaluation of the component position, alignment, polyethylene wear, and bony changes around the hip. Acetabular component positioning is most commonly described with two angles: inclination angle (also called abduction angle) and anteversion angle. Inclination angle is defined as the angle between transverse axis and the opening face of the cup in the coronal plane [12]. Inclination angle can be measured reliably with radiographs (Figure 1-4). Anteversion is the angle between the longitudinal axis and the opening face of the cup in the sagittal plane. The most accurate way to measure anteversion is by using advanced cross-sectional imaging in the form of computed tomography, rather than plain radiographs [13]. However, computed tomography is not practical to ascertain component position due to the associated cost and radiation exposure to the patient. Radiographs, therefore, are more appropriate from a fiscal and health safety standpoint to determine the anteversion angle. Unfortunately, a single radiographic method to measure anteversion of the acetabular component has not been agreed upon in literature. Anteversion has been measured in literature by the use of protractors [14]. Other studies measured major and minor diameters of the acetabular component as seen on AP radiographs to calculate version using mathematical formulas [13, 15]. Edge detection software also uses this concept with digitized AP radiographs. Edge detection software have been described as a valid method to measure anteversion but remain time-consuming [16]. Furthermore, clinicians do not have ready access to edge detection software, limiting its usefulness. Woo and Morey's method (Figure 1-5) and ischiolateral method (Figure 1-6) utilize cross-table lateral radiographs to measure anteversion [17-19]. Woo and Morey's method measures the angle between a line perpendicular to the horizontal plane of the radiograph and the opening face of the acetabular component. Ischiolateral method, on the other hand, uses a reference line perpendicular to the long axis of the ischium. The angle between this reference line and the opening face of the acetabulum on cross-table lateral view determines the radiographic anteversion of the acetabular component. This

dissertation utilizes the ischiolateral method, which is practical and has previously been shown to be comparable to edge detection software [18].

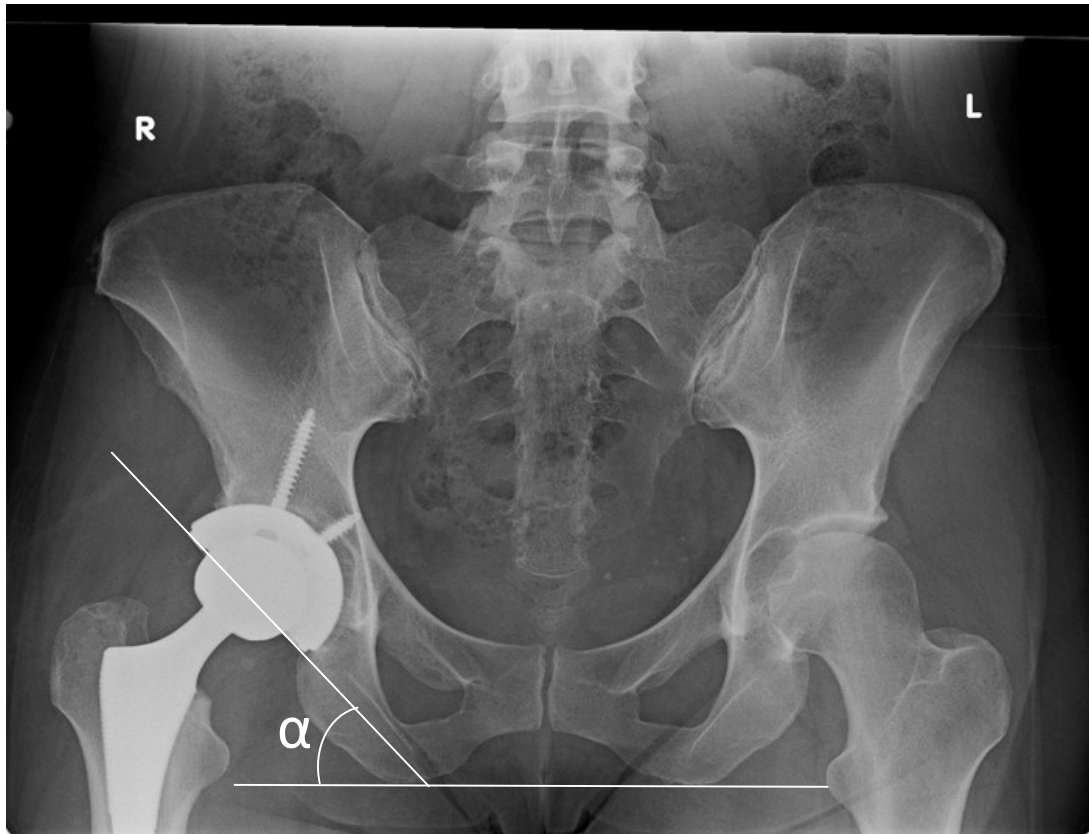


Figure 1-4: Measurement of inclination angle.

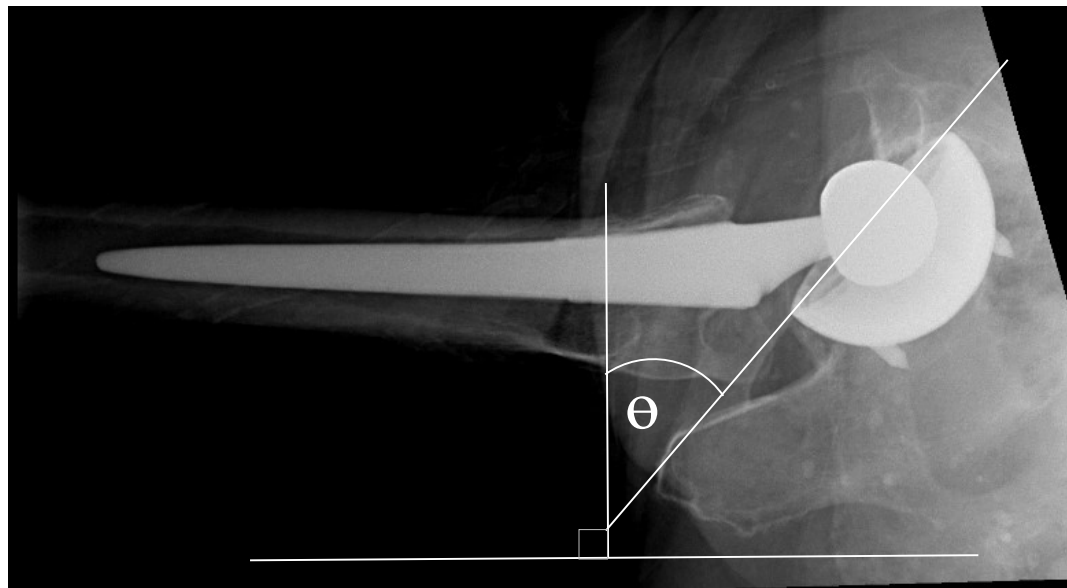


Figure 1-5: Measurement of anteversion angle using the Woo and Morrey Method

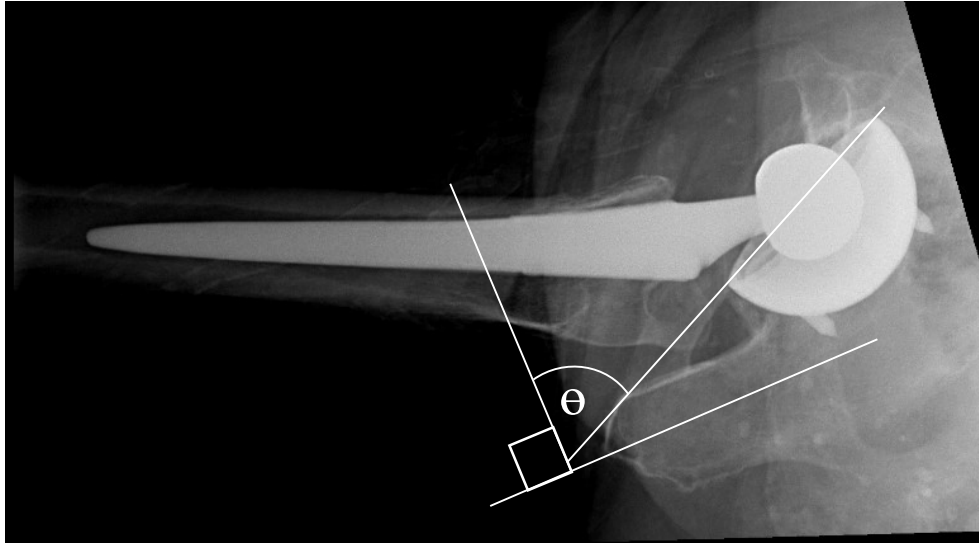


Figure 1-6: Measurement of anteversion angle using the Ischiolateral method.

Although, improvements in material designs have allowed reduction in wear rates, polyethylene liner wear is still a cause for revision THA surgery. Polyethylene debris has been known to induce osteolysis (resorption of bone matrix by increased macrophage activity) with associated aseptic loosening of the implants and increased revision rates [20-22]. Acetabular orientation is thought to be one of the factors that affects polyethylene wear [23], and is directly controlled by the surgeon. A clear correlation between acetabular position and polyethylene wear is not yet elucidated, however. Some studies have linked increased abduction angle greater than 45 degrees with increased polyethylene wear [24-27], while other studies have failed to show the same results [28-30]. Optimal cup position has been demonstrated to be most sensitive to anteversion angle of acetabulum [31], however, an association between anteversion and wear has not been described thus far.

Wear measurements are typically performed on radiographs using one of many different techniques, but essentially evaluate penetration of the femoral head into the polyethylene liner (thus into the acetabular cup) over time. Traditionally, plain radiographs at regular intervals post-operatively were used to measure polyethylene wear manually using the Livermore method [32]. The Dorr and Wan technique [33] and digital programs were subsequently introduced to measure wear on digitized radiographs. Common software programs include Martell's "Hip Analysis Suite" [34] and Devane's "PolyWare" [35,

36]. These measurements were reliable for conventional polyethylene liner, which experienced a large volume of wear, making measurements of head penetration simpler. Modern designs of polyethylene liners have improved wear properties decreasing the amount of wear [37]. Traditional measurement techniques are less sensitive and therefore, are less reliable in accurately measuring smaller magnitudes of polyethylene wear. The gold standard technique to measure polyethylene liner wear is radiostereometric analysis (RSA) [38, 39]. RSA utilizes two simultaneous radiograph acquisitions of the patient's hip taken at oblique angles. A calibration cage is also positioned within the acquisition area, consisting of two grids of marker beads placed at known locations with accuracy on the scale of micrometres. By identifying these markers on the resulting radiographic images using RSA software, the three-dimensional geometry of the bones, implants, and markers can be determined based on the known locations of the markers in three-dimensional space. Wear can then be calculated as the movement of the femoral head into the acetabular cup, similar to the other radiographic methods, but with a higher degree of accuracy. Dahl et al. recently introduced a novel method for calculating wear from a single pair of RSA exams (i.e. non-prospectively) by estimating the original post-operative location of the femoral head with respect to the cup [40]. Dahl's method is implemented in Chapter 4 of this dissertation, using a novel RSA setup that mimics a conventional clinical radiographic setup of AP and cross-table lateral view angles, enabling measurements of cup inclination and anteversion in addition to wear calculations from the RSA images.

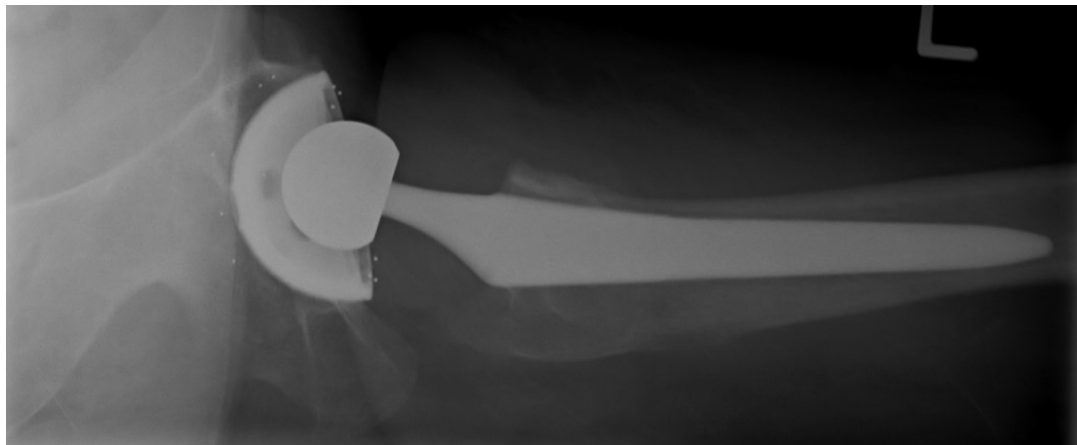


Figure 1-7: Lateral view of a THA with implantation of tantalum marker beads.

1.6 Importance of Acetabular Component Positioning

The positioning of the acetabular component is a crucial step of the surgical technique. The acetabular component must be aligned correctly in all planes - sagittal, coronal and axial. The position of the acetabular component in the medial-lateral direction influences offset leading to changes in the moment-lever arm of the abductor musculature. The anteversion of the acetabular cup in the sagittal plane and the inclination angle (also known as abduction angle) in the coronal plane are both important determinants of acetabular position.

During the implantation process, surgeons use different techniques to judge the positioning of the acetabular component. Pre-operative planning is performed using implant-specific computer programs to aid surgeons in determining the amount of overhang of the acetabular component past the pelvic bone. This can be used as an indirect measurement to evaluate anteversion and inclination angles. Mechanical alignment guides are often used to determine inclination and anteversion angles (Figure 1-8). Different pelvic bony landmarks may also be utilized to accurately position the acetabular component. Sotereanos et al. suggested the use of three osseous pelvic landmarks: the lowest point of the acetabular sulcus of the ischium, the prominence of the superior pelvic ramus, and the most superior point of the acetabular rim [41]. McCollum and Gray recommended the use of the sciatic notch [42] while Maruyama et al. advocated using the acetabular notch angle [43]. Ha et al. later suggested using transverse acetabular notch in combination with anterior acetabular notch for orientation of the cup [44]. These methods allow surgeons to account for individual variations in the hip and pelvic anatomy. Soft tissue landmarks may also be used as a reference. Archbold et al. described the use of transverse acetabular ligament and labrum as a reference to judge height, depth and anteversion of the cup [45, 46].

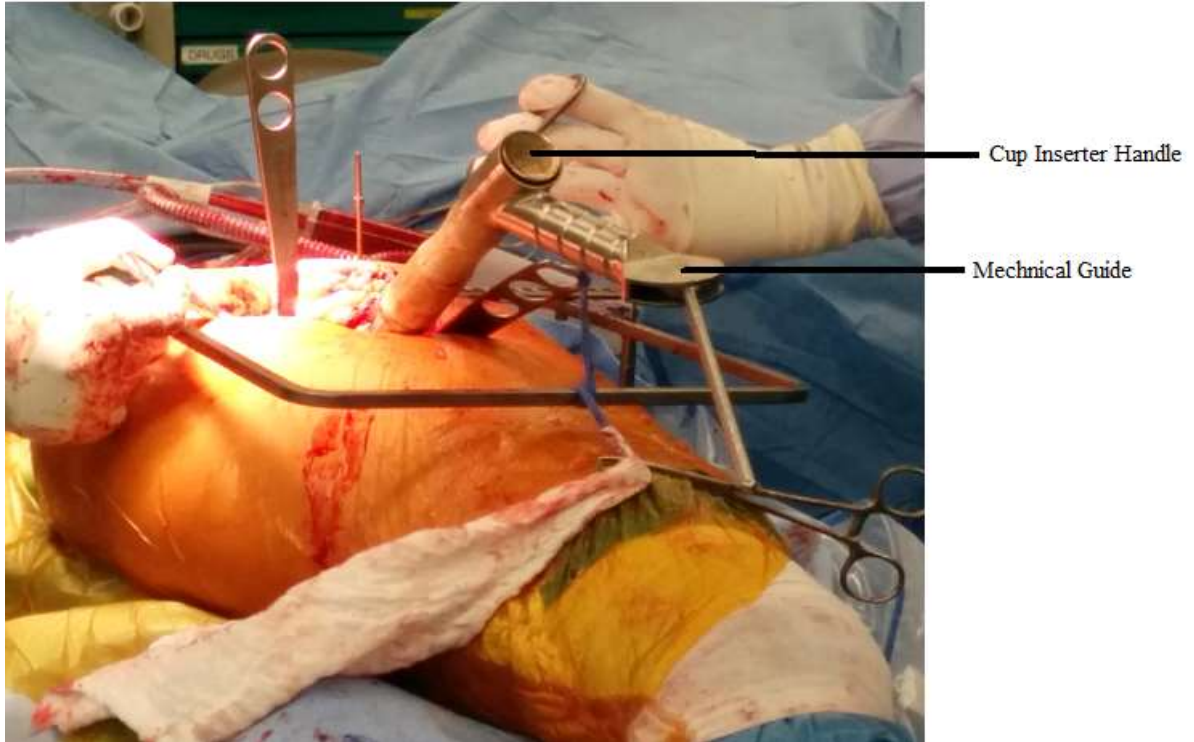


Figure 1-8: Mechanical alignment guide.

The guide attaches to the inserter handle of the acetabular component. The operative cup anteversion is referenced against the longitudinal axis of the body.

A number of complications have been attributed to malpositioning of the acetabular component. Improper acetabular orientation has been linked to increased dislocation rates [15, 42, 47-49], polyethylene wear [23], edge loading [50], liner fracture [51], and component impingement affecting range of motion [51-55]. Although other patient and technical factors may influence these complications, acetabular orientation remains under the direct control of the surgeon and must be optimized. Obtaining accuracy with positioning of the acetabular component, however, has proven to be very challenging. Many factors affect surgeon's ability to accurately position the acetabular component. These may include increased BMI, surgical approach, surgeon volume, surgeon experience and inherent inaccuracies in mechanical guides [23]. Furthermore, pelvic orientation can be influenced by the position on the body, thereby affecting the cup position. The lateral decubitus positioning causes increased flexion and adduction of the pelvis [42]. Furthermore, lateral positioning tends to flatten the lordotic curvature of the lumbar spine [42]. These changes in positioning can affect the accuracy of the cup orientation if they are not taken into consideration during the operative procedure.

Dislocation is one of the most common and devastating complications after THA [23]. Acetabular positioning directly influences dislocation rates. It is, therefore, no surprise that majority of the literature attempting to discern an ideal orientation for the acetabular component is based on reducing dislocation rates. Although the recent use of larger femoral heads dramatically reduced dislocation rates [56], they are not considered a substitute for a proper cup positioning. Lewinnek et al. showed that cups with an anteversion of 15 ± 10 degrees and inclination angle of 40 ± 10 degrees had 1.5% dislocation rates, while acetabular components outside this “safe zone” had a dislocation rate of 6.1% [15]. This historic paper, however, has been challenged in literature due to its methodology. Other authors have since attempted to re-define the optimal acetabular position based on biomechanical and clinical studies (Table 1). The ideal acetabular position, however, still remains a topic of debate.

Table 1-1: Review of previous studies attempting to define ideal inclination and anteversion angles.

| Study | Ideal inclination* | Ideal anteversion* | Other orientations |
|-------------------------|-------------------------|-------------------------|--|
| Lewinnek et al. [15] | $40^\circ \pm 10^\circ$ | $15^\circ \pm 10^\circ$ | |
| Dorr et al. [57] | $35^\circ \pm 15^\circ$ | $15^\circ \pm 15^\circ$ | |
| McCollum and Gray [42] | $40^\circ \pm 10^\circ$ | $30^\circ \pm 10^\circ$ | |
| Biedermann et al. [58] | $45^\circ \pm 10^\circ$ | $15^\circ \pm 10^\circ$ | |
| Barrack et al. [59] | $45^\circ \pm 10^\circ$ | $20^\circ \pm 10^\circ$ | |
| Widmer and Zurfluh [53] | $40^\circ-45^\circ$ | $20^\circ-28^\circ$ | $\beta + 0.7\delta = 37^\circ$ |
| Yoshimine [60] | | | $\alpha + \beta + 0.77\delta = 84.3^\circ$ |
| Jolles et al. [49] | | | $40^\circ < \beta + \delta < 60^\circ$ |
| Elkins et al. [31] | $45-55^\circ$ | $10-20^\circ$ | |

* Values are mean \pm range; α = cup inclination; β = cup anteversion; δ = femoral stem anteversion.

Acetabular malpositioning has also been shown to cause catastrophic polyethylene failure. Tower et al. have previously shown that having an inclination angle of greater than 65 degrees combined with a thin polyethylene rim (in the case of highly crosslinked polyethylene, which has decreased mechanical properties) increases the risk of polyethylene liner failures [61]. The position of the acetabular component also influences range of motion of the hip joint. Based on computer modelling, it has been shown that acetabular inclination of less than 45 degrees decreases flexion and abduction of the hip, while increased inclination angles decrease adduction and rotation [54].

Increasing anteversion angle has been shown to increase flexion with decreased extension of the hip [54]. Impingement pain has also been shown to be linked to malpositioning of the acetabular component. Iliopsoas tendonitis has been shown to be associated with a retroverted cup, whereby the exposed anterior rim of the cup can cause inflammation of the tendon [62]. Moreover, acetabular malpositioning has been shown to cause increased wear in metal-on-metal bearings [63].

1.7 Research Objectives

The objective of this dissertation is to further our current understanding in acetabular positioning. To date, there has been a lack of studies elucidating the accuracy of the modified Hardinge approach in orienting the acetabular component. Barrack et al. [64] and Callanan et al. [65] have previously investigated risk factors for cup malpositioning. These studies described the accuracy of posterior and anterolateral approaches. However, only a small group of patients who had a THA performed through the modified Hardinge approach was included in these studies. Chapter 2 of this dissertation highlights the accuracy of the modified Hardinge approach in an attempt to gain more comprehensive understanding of the surgical approaches at the disposal of orthopaedic surgeons.

A large number of studies have attempted to define a “safe zone” for acetabular component orientation based on dislocation rates (shown in Table 1). There has been a deficit in literature demonstrating the effect of acetabular positioning on patient reported functional outcome scores. A “safe zone” based on functional outcomes has not been clearly discerned in literature. Grammatopoulos et al. recently recommended an inclination of 45 degrees and anteversion of 25 degrees based solely on the Oxford Hip Score [66]. Chapter 3 correlates the functional outcome data with acetabular position using other outcome measures including Short Form-12, Harris Hip Score and Western Ontario and McMaster Universities Osteoarthritis Index.

Polyethylene wear has been shown to be higher in patients with increased acetabular inclination angle [24-27, 67, 68]. Reports using more accurate measurement techniques for wear have disputed this correlation [29, 69, 70]. Furthermore, most of these studies have been performed only on conventional polyethylene. As conventional polyethylene

has been substituted with highly cross-linked polyethylene, these associations need to be re-examined with newer materials, which have significantly improved wear characteristics [37]. Moreover, a clear relationship between anteversion and acetabular component orientation has not been established. Chapter 4, therefore, explores association between acetabular position and polyethylene wear.

1.8 References

1. Clohisy J, et al. *The Adult Hip: Hip Preservation Surgery*. 2015: Lippincott Williams & Wilkins.
2. Callaghan J, Rosenberg J, Rubash H. *The Adult Hip*, 2nd Edition. 2007: Lippincott Williams & Wilkins.
3. Hunter DJ. Osteoarthritis. *Best Pract Res Clin Rheumatol*, 2011. 25(6): p. 801-14.
4. Johnson VL, Hunter DJ. The epidemiology of osteoarthritis. *Best Pract Res Clin Rheumatol*, 2014. 28(1): p. 5-15.
5. Tarride JE, et al. The excess burden of osteoarthritis in the province of Ontario, Canada. *Arthritis Rheum*, 2012. 64(4): p. 1153-61.
6. Learmonth ID, Young C, and Rorabeck C. The operation of the century: total hip replacement. *The Lancet*, 2007. 370(9597): p. 1508-19.
7. Mu Z, et al. A systematic review of radiological outcomes of highly cross-linked polyethylene versus conventional polyethylene in total hip arthroplasty. *Int Orthop*, 2009. 33(3): p. 599-604.
8. Canadian Institute for Health Information. *Hip and Knee Replacements in Canada: Canadian Joint Replacement Registry 2014 Annual Report*, 2014.
9. Ethgen O, et al. Health-related quality of life in total hip and total knee arthroplasty. A qualitative and systematic review of the literature. *J Bone Joint Surg Am*, 2004. 86-a(5): p. 963-74.
10. Ramesh M, et al. Damage to the superior gluteal nerve after the Hardinge approach to the hip. *J Bone Joint Surg Br*, 1996. 78(6): p. 903-6.
11. Kellgren JH, Lawrence JS. Radiological assessment of osteo-arthritis. *Ann Rheum Dis*, 1957. 16(4): p. 494-502.
12. Massin P, Schmidt L, Engh CA. Evaluation of cementless acetabular component migration. An experimental study. *J Arthroplasty*, 1989. 4(3): p. 245-51.
13. Kalteis T, et al. Position of the acetabular cup -- accuracy of radiographic calculation compared to CT-based measurement. *Eur J Radiol*, 2006. 58(2): p. 294-300.
14. Liaw CK, et al. A new tool for measuring cup orientation in total hip arthroplasties from plain radiographs. *Clin Orthop Relat Res*, 2006. 451: p. 134-9.
15. Lewinnek GE, et al. Dislocations after total hip-replacement arthroplasties. *J Bone Joint Surg Am*, 1978. 60(2): p. 217-20.
16. Langton DJ, et al. The effect of component size and orientation on the concentrations of metal ions after resurfacing arthroplasty of the hip. *J Bone Joint Surg Br*, 2008. 90(9): p. 1143-51.
17. Woo RY, Morrey BF. Dislocations after total hip arthroplasty. *J Bone Joint Surg Am*, 1982. 64(9): p. 1295-306.
18. Tiberi JV, et al. A more reliable method to assess acetabular component position. *Clin Orthop Relat Res*, 2012. 470(2): p. 471-6.
19. Pulos N, Tiberi JV, Schmalzried TP. Measuring acetabular component position on lateral radiographs - ischio-lateral method. *Bull NYU Hosp Jt Dis*, 2011. 69 Suppl 1: p. S84-9.
20. Sochart DH. Relationship of acetabular wear to osteolysis and loosening in total hip arthroplasty. *Clin Orthop Relat Res*, 1999. 363: p. 135-50.

21. Oparaugo PC, et al. Correlation of wear debris-induced osteolysis and revision with volumetric wear-rates of polyethylene: a survey of 8 reports in the literature. *Acta Orthop Scand*, 2001. 72(1): p. 22-8.
22. Dumbleton JH, Manley MT, Edidin AA. A literature review of the association between wear rate and osteolysis in total hip arthroplasty. *J Arthroplasty*, 2002. 17(5): p. 649-61.
23. Daines BK, Dennis DA. The importance of acetabular component position in total hip arthroplasty. *Orthop Clin North Am*, 2012. 43(5): p. e23-34.
24. Patil S, et al. Polyethylene wear and acetabular component orientation. *J Bone Joint Surg Am*, 2003. 85-A Suppl 4: p. 56-63.
25. Schmalzried TP, et al. The relationship between the design, position, and articular wear of acetabular components inserted without cement and the development of pelvic osteolysis. *J Bone Joint Surg Am*, 1994. 76(5): p. 677-88.
26. Kennedy JG, et al. Effect of acetabular component orientation on recurrent dislocation, pelvic osteolysis, polyethylene wear, and component migration. *J Arthroplasty*, 1998. 13(5): p. 530-4.
27. Hirakawa K, et al. Effect of acetabular cup position and orientation in cemented total hip arthroplasty. *Clin Orthop Relat Res*, 2001. 388: p. 135-42.
28. Korduba LA, et al. Effect of acetabular cup abduction angle on wear of ultrahigh-molecular-weight polyethylene in hip simulator testing. *Am J Orthop (Belle Mead NJ)*, 2014. 43(10): p. 466-71.
29. Ito M, et al. The effect of cup placement in cementless total hip arthroplasty on the wear rate of polyethylene. *Orthopedics*, 2008. 31(3): p. 225-35.
30. Goosen JH, Verheyen CC, Tulp NJ. Mid-term wear characteristics of an uncemented acetabular component. *J Bone Joint Surg Br*, 2005. 87(11): p. 1475-9.
31. Elkins JM, Callaghan JJ, Brown TD. The 2014 Frank Stinchfield Award: The 'landing zone' for wear and stability in total hip arthroplasty is smaller than we thought: a computational analysis. *Clin Orthop Relat Res*, 2015. 473(2): p. 441-52.
32. Livermore J, Ilstrup D, Morrey B. Effect of femoral head size on wear of the polyethylene acetabular component. *J Bone Joint Surg Am*, 1990. 72(4): p. 518-28.
33. Dorr LD, Wan Z. Ten years of experience with porous acetabular components for revision surgery. *Clin Orthop Relat Res*, 1995. 319: p. 191-200.
34. Martell JM, Berdia S. Determination of polyethylene wear in total hip replacements with use of digital radiographs. *J Bone Joint Surg Am*, 1997. 79(11): p. 1635-41.
35. Devane PA, et al. Measurement of polyethylene wear in metal-backed acetabular cups. I. Three-dimensional technique. *Clin Orthop Relat Res*, 1995. 319: p. 303-16.
36. Devane PA, et al. Measurement of polyethylene wear in metal-backed acetabular cups. II. Clinical application. *Clin Orthop Relat Res*, 1995. 319: p. 317-26.
37. Muratoglu OK, et al. A novel method of cross-linking ultra-high-molecular-weight polyethylene to improve wear, reduce oxidation, and retain mechanical properties. *J Arthroplasty*, 2001. 16(2): p. 149-60.

38. Bragdon CR, et al. Comparison of femoral head penetration using RSA and the Martell method. *Clin Orthop Relat Res*, 2006. 448: p. 52-7.
39. Stilling M, et al. Superior accuracy of model-based radiostereometric analysis for measurement of polyethylene wear: A phantom study. *Bone Joint Res*, 2012. 1(8): p. 180-91.
40. Dahl J, et al. Center index method-an alternative for wear measurements with radiostereometry (RSA). *J Orthop Res*, 2013. 31(3): p. 480-4.
41. Sotereanos NG, et al. Using intraoperative pelvic landmarks for acetabular component placement in total hip arthroplasty. *J Arthroplasty*, 2006. 21(6): p. 832-40.
42. McCollum DE, Gray WJ. Dislocation after total hip arthroplasty. Causes and prevention. *Clin Orthop Relat Res*, 1990. 261: p. 159-70.
43. Maruyama M, et al. The Frank Stinchfield Award: Morphologic features of the acetabulum and femur: anteversion angle and implant positioning. *Clin Orthop Relat Res*, 2001. 393: p. 52-65.
44. Ha YC, et al. Acetabular component positioning using anatomic landmarks of the acetabulum. *Clin Orthop Relat Res*, 2012. 470(12): p. 3515-23.
45. Archbold HA, et al. The transverse acetabular ligament: an aid to orientation of the acetabular component during primary total hip replacement: a preliminary study of 1000 cases investigating postoperative stability. *J Bone Joint Surg Br*, 2006. 88(7): p. 883-6.
46. Archbold HA, et al. The relationship of the orientation of the transverse acetabular ligament and acetabular labrum to the suggested safe zones of cup positioning in total hip arthroplasty. *Hip Int*, 2008. 18(1): p. 1-6.
47. Ali Khan M, Brakenbury P, Reynolds I. Dislocation following total hip replacement. *J Bone Joint Surg Br*, 1981. 63-B(2): p. 214-218.
48. Robinson M, et al. Effect of restoration of combined offset on stability of large head THA. *Hip Int*, 2012. 22(3): p. 248-53.
49. Jolles BM, Zangger P, Leyvraz PF. Factors predisposing to dislocation after primary total hip arthroplasty: a multivariate analysis. *J Arthroplasty*, 2002. 17(3): p. 282-8.
50. Leslie IJ, et al. High cup angle and microseparation increase the wear of hip surface replacements. *Clin Orthop Relat Res*, 2009. 467(9): p. 2259-65.
51. Yamaguchi M, et al. The spatial location of impingement in total hip arthroplasty. *J Arthroplasty*, 2000. 15(3): p. 305-313.
52. Shon WY, et al. Impingement in Total Hip Arthroplasty: A Study of Retrieved Acetabular Components. *J Arthroplasty*, 2005. 20(4): p. 427-435.
53. Widmer KH, Zurfluh B. Compliant positioning of total hip components for optimal range of motion. *J Orthop Res*, 2004. 22(4): p. 815-21.
54. D'Lima DD, et al. The effect of the orientation of the acetabular and femoral components on the range of motion of the hip at different head-neck ratios. *J Bone Joint Surg Am*, 2000. 82(3): p. 315-21.
55. Williams D, Royle M, Norton M. Metal-on-Metal Hip Resurfacing: The Effect of Cup Position and Component Size on Range of Motion to Impingement. *J Arthroplasty*, 2009. 24(1): p. 144-151.

56. Malkani AL, et al. Early- and late-term dislocation risk after primary hip arthroplasty in the Medicare population. *J Arthroplasty*, 2010. 25(6 Suppl): p. 21-5.
57. Dorr LD, et al. Classification and treatment of dislocations of total hip arthroplasty. *Clin Orthop Relat Res*, 1983. 173: p. 151-8.
58. Biedermann R, et al. Reducing the risk of dislocation after total hip arthroplasty: the effect of orientation of the acetabular component. *J Bone Joint Surg Br*, 2005. 87(6): p. 762-9.
59. Barrack RL, et al. Virtual reality computer animation of the effect of component position and design on stability after total hip arthroplasty. *Orthop Clin North Am*, 2001. 32(4): p. 569-77.
60. Yoshimine F. The safe-zones for combined cup and neck anteversions that fulfill the essential range of motion and their optimum combination in total hip replacements. *J Biomech*, 2006. 39(7): p. 1315-23.
61. Tower SS, et al. Rim cracking of the cross-linked longevity polyethylene acetabular liner after total hip arthroplasty. *J Bone Joint Surg Am*, 2007. 89(10): p. 2212-7.
62. Trousdale RT, Cabanela ME, Berry DJ. Anterior iliopsoas impingement after total hip arthroplasty. *J Arthroplasty*, 1995. 10(4): p. 546-9.
63. Hart AJ, et al. The relationship between the angle of version and rate of wear of retrieved metal-on-metal resurfacings: a prospective, CT-based study. *J Bone Joint Surg Br*, 2011. 93(3): p. 315-20.
64. Barrack RL, et al. Accuracy of acetabular component position in hip arthroplasty. *J Bone Joint Surg Am*, 2013. 95(19): p. 1760-8.
65. Callanan MC, et al. The John Charnley Award: risk factors for cup malpositioning: quality improvement through a joint registry at a tertiary hospital. *Clin Orthop Relat Res*, 2011. 469(2): p. 319-29.
66. Grammatopoulos G, et al. The effect of orientation of the acetabular component on outcome following total hip arthroplasty with small diameter hard-on-soft bearings. *Bone Joint J*, 2015. 97-b(2): p. 164-72.
67. Wan Z , Boutary M, Dorr LD. The influence of acetabular component position on wear in total hip arthroplasty. *J Arthroplasty*, 2008. 23(1): p. 51-6.
68. Gallo J, Havranek V, Zapletalova J. Risk factors for accelerated polyethylene wear and osteolysis in ABG I total hip arthroplasty. *Int Orthop*, 2010. 34(1): p. 19-26.
69. Del Schutte H, et al. Effects of acetabular abduction on cup wear rates in total hip arthroplasty. *J Arthroplasty*, 1998. 13(6): p. 621-6.
70. Kligman M, Michael H, Roffman M. The effect of abduction differences between cup and contralateral acetabular angle on polyethylene component wear. *Orthopedics*, 2002. 25(1): p. 65-7.

Chapter 2

2 Accuracy of the Modified Hardinge Approach in Acetabular Positioning

2.1 Introduction

Acetabular component positioning is paramount for successful total hip arthroplasty. Poor cup positioning affects impingement [1-5], dislocation rates [6-10], edge loading [11], and may lead to liner fractures [3]. Studies have shown that excess abduction angle is correlated with increased bearing surface wear rates in metal-on-polyethylene and metal-on-metal articulations [12-15]. In metal-on-metal hip resurfacing, Hart et al. showed increased blood metal ion levels in patients with insufficient cup version [16]. However, acceptable cup position has been defined only in reference to dislocation rates and its definition has been largely inconsistent in the literature. Lewinnek et al. defined a “safe zone” of 15 ± 10 degrees of anteversion and inclination angle of 40 ± 10 degrees based on nine dislocations [6]. Meanwhile, McCollum and Gray suggested the cup to be placed between 20 and 40 degrees of anteversion based on five dislocations [8]. Although the Lewinnek’s “safe zone” is considered obsolete by many surgeons [17, 18], it is often used in the literature to allow consistent comparison of outcomes.

Surgical approach may influence dislocation rates, post-operative function, heterotopic ossification, and the possibility of neurovascular damage [19-24]. The selection of surgical approach is largely a matter of preference based on prior training of the surgeon. Callanan et al. identified surgical approach to be an independent risk factor in cup malpositioning [25]. They identified a 68% incidence of cup malpositioning with the use of the direct lateral approach compared to 42.7% when using the posterolateral approach. Barrack et al. only had 21% of the cups positioned outside their defined range using the anterolateral approach [26]. Both studies, however, used different acceptable ranges for the cup position with an emphasis on the posterolateral approach as the most popular surgical approach at their centers. Furthermore, the lateral approaches were being

performed by low volume surgeons in both studies, making it difficult to determine the generalizability of the results.

The modified Hardinge is the most common surgical approach utilized at our institution for total hip replacements. This approach offers good visualization of the acetabulum, facilitating optimal cup positioning as well as excellent stability of the total hip joint. The purpose of this study is to evaluate the accuracy of intraoperative acetabular component positioning with use of the modified Hardinge approach performed by high-volume surgeons at a tertiary center.

2.2 Methods

Ethics approval was obtained from our institutional review board. Our institutional arthroplasty database was used to obtain patient information between 2003 and 2011 including their age, gender, date of their total hip arthroplasty, laterality of the hip, implant information and surgical approach utilized for the procedure. All total hip replacements were executed by eight fellowship trained high-volume surgeons, each performing more than 250 total joint replacements per year. Western Ontario and McMaster Universities Osteoarthritis index (WOMAC), Harris hip scores (HHS) and Short Form-12 (SF-12) scores collected prospectively were extracted from the database. Functional scores collected between 24 and 36 months following the procedure were used for analysis in this study.

A total of 1,010 hips were included in the current study. The study cohort consisted of patients with a diagnosis of osteoarthritis who underwent a cementless total hip arthroplasty with the use of the modified Hardinge approach. Patients were required to have digital post-operative radiographs collected prospectively, between 24 and 36 months from their index procedure and complete post-operative clinical outcome scores. We excluded patients with diagnosis of metastatic cancer, avascular necrosis, inflammatory arthritis, post-traumatic arthritis, acute fracture, development hip dysplasia, metal-on-metal articulations, cemented acetabular components, bipolar hemiarthroplasty, modular neck-stem implants and revision surgeries.

Acetabular components used in our cohort were all press fit, hemispherical shells, and included Reflection™ (Smith and Nephew, Memphis, TN), Duraloc® (Depuy, Warsaw, IN), R3™ (Smith and Nephew, Memphis, TN), Pinnacle® (Depuy, Warsaw, IN) and Trident® (Stryker®, Kalamazoo, MI).

The modified Hardinge approach has previously been detailed by Frndak et al [27]. Patients were in lateral decubitus position. A lateral skin incision centered over the greater trochanter was used. The access to the hip joint was gained through an abductor muscle split approach. The fibers of the gluteus medius were split longitudinally at the junction of anterior third to posterior two-thirds of the muscle belly. Gluteus minimus and capsule were then divided vertically along the same incision parallel to the gluteus medius split. Surgeons were attentive to keep the vertical split within 5 cm proximal to greater trochanter to avoid injury to the superior gluteal nerve. During pre-operative templating and the implantation of the cup, surgeons aimed the operative inclination and anteversion angles of the acetabular component to be within the Lewinnek's zone. A combination of anatomic landmarks and mechanical guides were used intraoperatively.

Anteroposterior (AP) and lateral radiographs were examined for the purposes of this study. Using General Electric Centricity™ Picture Archiving and Communications System (PACS), we measured the radiographic inclination angle and anteversion. Radiographs were analyzed by two observers (PG and AL). A subset of the population was measured by both to calculate the concordance correlation coefficient to confirm adequate inter-observer reliability, which was consistently greater than 0.93. Differences in measurements, when present, were reconciled through mutual agreement. Anteversion was measured using the ischiolateral method described by Tiberi et al. [28]. Inclination angle was measured between the face of the acetabular component and the horizontal axis drawn by connecting the ischial tuberosities [6, 29, 30].

Statistical analysis was performed using SPSS® statistics version 20 (IBM®, NY). Frequency analysis, and chi-squared tests were performed to obtain accuracy of the modified Hardinge approach at our institution. A univariate analysis was performed with five factors including age, sex, body mass index (BMI), head size and outer acetabular

component diameter. Multivariate analysis was performed using logistic regression with the same five variables. A p-value of less than 0.05 was considered significant.

2.3 Results

Mean anteversion was 21.8 ± 11.8 degrees and the mean inclination was 44.32 ± 7.0 degrees. At the time of procedure, the mean age of the study population was 71.5 ± 9.6 years. There were 595 females (59%) and 415 males (41%). The majority of the procedures (543, or 53.7%) were performed on the right hip. The average BMI was 29.6 ± 6.1 kg/m². Functional outcome scores are reported in Table 2-1.

Table 2-1: Post-operative outcome scores of patients who underwent the modified Hardinge approach for their total hip arthroplasty.

| Outcome Score | Mean | Std. Deviation |
|---------------------------|-------|----------------|
| <u>WOMAC</u> | | |
| Pain (n=952) | 83.05 | 20.36 |
| Stiffness (n=954) | 76.77 | 21.57 |
| Physical Function (n=944) | 79.01 | 20.07 |
| Total (n=944) | 80.21 | 18.71 |
| <u>Harris Hip Score</u> | | |
| Pain (n=872) | 41.64 | 5.37 |
| Function (n=819) | 39.80 | 7.65 |
| Total (n=793) | 90.20 | 10.69 |
| <u>Short Form-12</u> | | |
| Physical Score (n=973) | 40.67 | 11.16 |
| Mental Score (n=973) | 54.05 | 9.29 |

The accuracy of achieving the targeted cup position is reported in Table 2-2. Accuracy was best for inclination, with 79.2% of the hips meeting the target inclination angle. For anteversion, 54.1% of the hips had their cup in the intended range. Examining combined inclination and anteversion angles, 43.6% of the hips had the acetabular component within the target range. The position of acetabular components in all patients are graphically represented in Figure 2-1. We found that 47.5% of the hips were within one standard deviation of the mean of combined anteversion and inclination angle while 90.5% were within two standard deviations (Table 2-3).

Table 2-2: Comparison of cup positioning accuracy between different approaches as demonstrated in previous studies.

| | Number of hips | Optimal Range of Inclination Angle | Optimal Range of Anteversion | Components within both ranges |
|-----------------------------|----------------|------------------------------------|------------------------------|-------------------------------|
| Callanan et al. [25] | 1952 | 30° - 45° | 5° - 25° | |
| Direct Lateral | 50 | | | 32.0% |
| Posterolateral | 1170 | | | 57.3% |
| Anterolateral | 560 | | | 37.0% |
| Barrack et al. [26] | 1549 | 30° - 55° | 5° - 35° | |
| Posterolateral | 898 | | | 88.0% |
| Anterolateral | 154 | | | 79.0% |
| Current study | 1010 | 30° - 50° | 5° - 25° | |
| Modified Hardinge | | | | 43.6% |

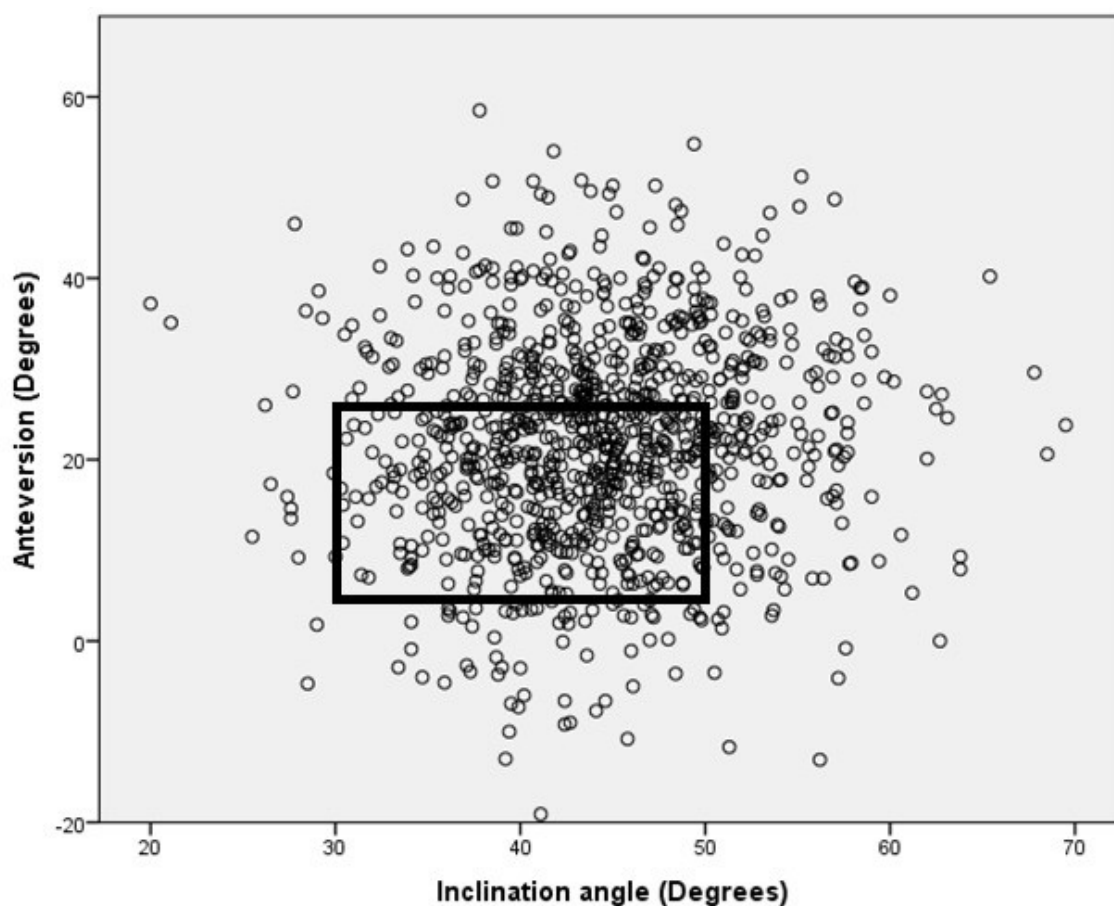


Figure 2-1: A scatter-diagram summary of the orientation of the acetabular components in the study population.

Data highlighted within the black box indicates the cups within the Lewinnek's "safe zone".

Table 2-3: Distribution of the hips within described range of anteversion and inclination angle.

| | Inclination Angle | | Anteversion | | Components within both ranges, n |
|-------------|-------------------|-----------------------------|---------------|-----------------------------|----------------------------------|
| | Range | Number of hips within range | Range | Number of hips within range | |
| Total Range | 20° – 70° | 1010 (100%) | -19° - 59° | 1010 (100%) | 100% |
| Mean ± 1SD | 37.4° – 51.3° | 705 (69.8%) | 10.1° -33.6° | 685 (67.8%) | 480 (47.5%) |
| Mean ± 2SD | 30.4° -58.2° | 965 (95.5%) | -1.7° - 45.4° | 958 (94.9%) | 915 (90.6%) |

The results of the univariate analysis for age, sex, BMI, head size and outer acetabular component diameter are shown in Table 2-4. BMI and gender of the patient had a significant effect on combined position of the acetabular component. Males were more likely to have a correctly oriented acetabular component when compared to females ($p<0.001$). Furthermore, patients with lower BMI were more likely to have an acetabular component with inaccurate anteversion and inclination angle ($p=0.02$). When acetabular inclination angle was examined separately, gender ($p<0.001$) and femoral head size ($p<0.001$) had an effect on acetabular inclination. Females and those with 28mm head sizes or smaller were more likely to have inclination angle outside the target zone. Akin to the combined absolute cup position, anteversion was similarly affected by gender ($p=0.009$) and body mass index ($p=0.002$). Figure 2-2 graphically illustrates a reduction in inclination angle over time (Spearman rho = -0.19, $p<0.001$).

Table 2-4: Univariate analysis of various factors for combined acetabular cup position within the Lewinnek's "safe zone".

| Factor | Number of hips | | | p-value |
|-----------------------------|----------------|------------------------|-------------------------|---------|
| | Total | Within Lewinnek's Zone | Outside Lewinnek's Zone | |
| | 1010 | 440 (43.6%) | 570 (56.4%) | |
| Age (n=1010) | | | | |
| ≤ 50 years | 36 | 19 (52.8%) | 17 (47.2%) | 0.331 |
| 50-70 years | 359 | 148 (41.2%) | 211 (58.8%) | |
| ≥70 years | 615 | 273 (44.4%) | 342 (55.6%) | |
| Sex (n=1010) | | | | |
| Male | 415 | 210 (50.6%) | 205 (49.4%) | <0.001 |
| Female | 595 | 230 (38.7%) | 365 (61.3%) | |
| BMI (n=965) | | | | |
| ≤24.99 | 214 | 71 (33.2%) | 143 (66.8%) | 0.02 |
| 25-29.99 | 343 | 165 (48.1%) | 178 (51.9%) | |
| 30-34.99 | 247 | 111 (44.9%) | 136 (55.1%) | |
| 35-39.99 | 101 | 50 (49.5%) | 51 (50.5%) | |
| ≥40 | 60 | 20 (33.3%) | 40 (66.7%) | |
| Head Size (n=1009) | | | | |
| ≤28mm | 291 | 118 (40.5%) | 173 (59.5%) | 0.316 |
| 32mm | 509 | 222 (43.6%) | 287 (56.4%) | |
| ≥36mm | 209 | 99 (47.4%) | 110 (52.6%) | |
| Outer Cup Diameter (n=1002) | | | | |
| <52mm | 44 | 16 (36.4%) | 28 (63.6%) | 0.061 |
| 52-56mm | 639 | 266 (41.6%) | 373 (58.4%) | |
| >56mm | 319 | 156 (48.9%) | 163 (51.1%) | |

Multivariate analysis demonstrated that patients with BMI between 25 and 40 were more likely to have correct combined acetabular component position compared to those with lower BMI (Table 2-5). Gender, age, head size and outer acetabular diameter were not independent risk factors to cup malpositioning.

Table 2-5: Multivariate analysis of factors for predicting accurate component position within the Lewinnek's zone (n=958).

| Factor | Reference Category | Odds Ratio (95% Confidence Interval) | p-value |
|--------------------------------------|--------------------|--------------------------------------|---------|
| Body Mass Index (kg/m ²) | | | |
| 25-29.99 | ≤24.99 | 1.78 (1.24 - 2.56) | 0.002 |
| 30 - 34.99 | | 1.53 (1.04 - 2.26) | 0.033 |
| 35 - 39.99 | | 2.07 (1.26 - 3.40) | 0.004 |
| ≥40 | | - | 0.868 |
| Sex | | | |
| Male | Female | 1.40 (1.00 – 1.95) | 0.05 |
| Age (years) | | | |
| 50-70 | ≤50 | - | 0.362 |
| ≥70 | | - | 0.549 |
| Head Size | | | |
| ≤28mm | 32mm | - | 0.444 |
| ≥36mm | | - | 0.957 |
| Outer cup diameter | | | |
| <52mm | 52-56mm | - | 0.894 |
| >56mm | | - | 0.653 |

2.4 Discussion

Using the Lewinnek's "safe zone", we found 43.6% of the cups were within the combined inclination and anteversion target using the modified Hardinge approach. There is no consensus in the literature to suggest the "ideal" position of the acetabular component. Barrack et al. used a wider range of 30-55 degrees and 5-35 degrees as their reference range for inclination angle and anteversion, respectively [26]. A direct comparison with the study performed by Barrack et al. was not possible, as they did not perform any of their surgeries using the Hardinge approach [26]. Callanan et al. obtained an accuracy of 32% using the direct lateral approach with a slightly narrower reference range consisting of 30-45 degrees of inclination and 5-25 degrees of anteversion [25]. Only low volume surgeons used the direct lateral approach in their study [25], potentially explaining the greater accuracy seen in our study, in which the surgeries were being performed only by high volume surgeons. Furthermore, the direct lateral group made up only 2.6% of the entire study cohort (50/1952), and therefore there is more potential for error in their reported results.

Among different studies, cup positioning accuracy varies between 32 and 88 percent depending on the approach and the target range [25, 26]. As shown in Table 2, Barrack et al. had combined accuracy of 88% and 79% mainly due to a wider reference range using the anterolateral and posterolateral approach, respectively [26]. Callanan et al. used a reference range comparable to the range targeted at our center [25]. They reported moderate accuracy in attaining cup position in all groups regardless of the approach used, which is comparable to the accuracy we obtained using the modified Hardinge approach.

Our study highlights females to be at risk to have inaccurate anteversion and inclination of their acetabular component. However, it was also found that females were more likely to have lower BMI compared to males ($p < 0.001$). The multivariate analysis also highlights this confounding phenomenon as the significance no longer meets the threshold value to establish gender as a risk factor for cup malpositioning. This suggests that differences in malpositioning seen with gender are confounded by BMI, a factor previously identified to affect placement of the cup and confirmed by our study [25, 26]. These studies demonstrated that patients with a higher BMI are more likely to have an incorrect position of the cup with their chosen reference range of anteversion and inclination. Our study, however, shows patients who have lower BMI were at risk for acetabular component malpositioning. Potential reasons for cup malposition in these patients include the use of smaller incisions, potential for patients with lower BMI to have different pelvic obliquity on the operative table and relatively lower number of patients with low BMI. Analogous to MIS approaches that use smaller incisions, we know that limited exposure is a risk factor for cup malpositioning [25].

The size of the acetabular cup was not a significant factor in cup malpositioning, which is consistent with current literature [25]. However, femoral head size was found to be an independent factor affecting inaccuracies in inclination angle. Smaller head sizes were associated with increased inclination angle. However, with further analysis, a temporal factor was demonstrated. Over time, the arthroplasty community has demonstrated an increased tendency to use larger diameter head sizes [31]. This widespread tendency was also evident in our data. Literature has demonstrated that increased inclination angle is associated with more polyethylene wear [12, 13, 15]. Concurrent with the trend to

increased head size is an increased understanding and acceptance of the effect of inclination and wear, resulting in tendency toward a decreased inclination angle (Figure 2-2). Therefore, the association of smaller head sizes with increased cup inclination has time as a confounding factor.

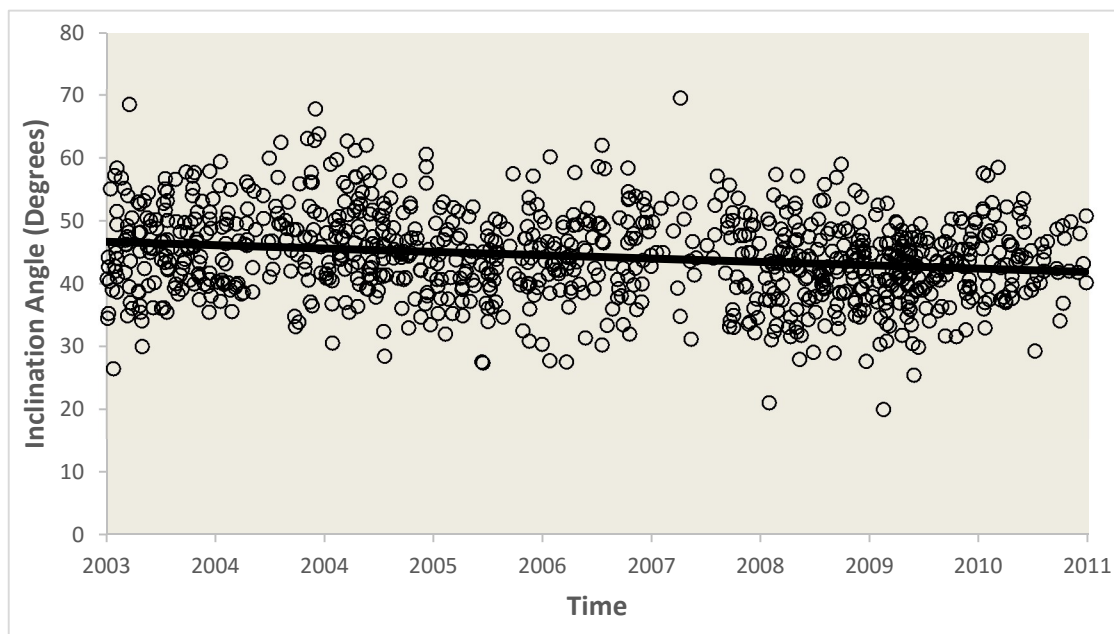


Figure 2-2: A temporal view of inclination angles of all hips from 2003 to 2011.
 $R^2 = 0.041$. $y = -0.0015x + 101.75$

Previous reports investigating acetabular positioning have relied on a variety of techniques to measure anteversion angles including edge detection software, computed tomography (CT) and with the sole use of anteroposterior radiographs centered on the hip [25, 26, 32-35]. We utilized the method outlined by Tiberi et al., which is comparatively reliable to edge detection software [28]. Overall, we found the mean inclination angle in our study to be comparable to studies in literature [25, 26, 32-35]. The mean anteversion angle of 21.82 degrees, however, found in our study is the highest amongst these studies.

Limitation of our study include the lack of a comparison group. A small proportion of total hip replacements were performed using other surgical approaches at our institution. However, these groups were too small to obtain any meaningful comparisons and could not be used (n = 53 hips performed using posterior approach, n = 7 were operated using anterior approach). The method used for anteversion measurements on routine radiographs is not standardized in literature. It is currently difficult to ascertain the

accuracy of radiographic measurements compared to CT scans as current reports in literature use variable reference planes to determine anteversion and inclination angles [36]. In order to be consistent, we used radiographic measurements using the radiographic coronal plane, currently used and understood by surgeons and therefore, practical.

Overall, our study is the largest to date that attempts to study the accuracy of cup positioning using the modified Hardinge approach performed by high volume surgeons. The sample size in the current is comparable to the reports in literature that have evaluated the posterolateral approach to establish the accuracy of cup positioning. Consistent with other studies examining other surgical approaches, we show that the modified Hardinge approach is moderately accurate in attaining accurate combined anteversion and inclination angle within a target range.

2.5 References

1. Shon WY, et al. Impingement in Total Hip Arthroplasty: A Study of Retrieved Acetabular Components. *J Arthroplasty*, 2005. 20(4): p. 427-35.
2. Widmer KH, Zurfluh B. Compliant positioning of total hip components for optimal range of motion. *J Orthop Res*, 2004. 22(4): p. 815-21.
3. Yamaguchi M, et al. The spatial location of impingement in total hip arthroplasty. *J Arthroplasty*, 2000. 15(3): p. 305-13.
4. D'Lima DD, et al. The effect of the orientation of the acetabular and femoral components on the range of motion of the hip at different head-neck ratios. *J Bone Joint Surg Am*, 2000. 82(3): p. 315-21.
5. Williams D, Royle M, Norton M. Metal-on-Metal Hip Resurfacing: The Effect of Cup Position and Component Size on Range of Motion to Impingement. *J Arthroplasty*. 2009. 24(1): p.144-51.
6. Lewinnek GE, et al. Dislocations after total hip-replacement arthroplasties. *J Bone Joint Surg Am*. 1978. 60(2): p.217-20.
7. Ali Khan M, Brakenbury P, Reynolds I. Dislocation following total hip replacement. *J Bone Joint Surg Br*. 1981 .63(2): p.214-18.
8. McCollum DE, Gray WJ. Dislocation after total hip arthroplasty. Causes and prevention. *Clin Orthop Relat Res*. 1990. 261: p. 159-70.
9. Robinson M, et al. Effect of restoration of combined offset on stability of large head THA. *Hip Int*, 2012. 22(3): p. 248-53.
10. Jolles BM, Zangger P, Leyvraz PF. Factors predisposing to dislocation after primary total hip arthroplasty: a multivariate analysis. *J Arthroplasty*, 2002. 17(3): p. 282-88.
11. Leslie IJ, et al. High cup angle and microseparation increase the wear of hip surface replacements. *Clin Orthop Relat Res*, 2009. 467(9): p. 2259-65.
12. Patil S, et al. Polyethylene wear and acetabular component orientation. *J Bone Joint Surg Am*, 2003. 85: p. 56-63.
13. Little NJ, et al. Acetabular polyethylene wear and acetabular inclination and femoral offset. *Clin Orthop Relat Res*, 2009. 467(11): p. 2895-2900.
14. Hart AJ, et al. The relationship between the angle of version and rate of wear of retrieved metal-on-metal resurfacings: a prospective, CT-based study. *J Bone Joint Surg Br*, 2011. 93(3): p. 315-20.
15. Schmalzried TP, et al. The relationship between the design, position, and articular wear of acetabular components inserted without cement and the development of pelvic osteolysis. *J Bone Joint Surg Am*, 1994. 76(5): p. 677-88.
16. Hart AJ, et al. Insufficient acetabular version increases blood metal ion levels after metal-on-metal hip resurfacing. *Clin Orthop Relat Res*, 2011. 469(9): p. 2590-97.
17. Eilander W, et al. Functional acetabular component position with supine total hip replacement. *Bone Joint J*, 2013. 95(10): p. 1326-31.

18. Murphy WS, et al. Pelvic tilt is minimally changed by total hip arthroplasty. *Clin Orthop Relat Res*, 2013. 471(2): p. 417-21.
19. Arthursson AJ, et al. Prosthesis survival after total hip arthroplasty--does surgical approach matter? Analysis of 19,304 Charnley and 6,002 Exeter primary total hip arthroplasties reported to the Norwegian Arthroplasty Register. *Acta Orthop*, 2007. 78(6): p. 719-729.
20. Colwell JCW. Instability after total hip arthroplasty. *Current Ortho Practice*, 2009. 20(1): p. 8-14.
21. Enocson A, et al. Dislocation of hemiarthroplasty after femoral neck fracture: better outcome after the anterolateral approach in a prospective cohort study on 739 consecutive hips. *Acta Orthop*, 2008. 79(2): p. 211-17.
22. Mallory TH, et al. Dislocation after total hip arthroplasty using the anterolateral abductor split approach. *Clin Orthop Relat Res*, 1999. 358: p. 166-72.
23. Abitbol JJ, et al. Gluteal nerve damage following total hip arthroplasty. A prospective analysis. *J Arthroplasty*, 1990. 5(4): p. 319-22.
24. Gore DR, et al. Anterolateral compared to posterior approach in total hip arthroplasty: differences in component positioning, hip strength, and hip motion. *Clin Orthop Relat Res*, 1982. 165: p. 180-87.
25. Callanan MC, et al. The John Charnley Award: risk factors for cup malpositioning: quality improvement through a joint registry at a tertiary hospital. *Clin Orthop Relat Res*, 2011. 469(2): p. 319-29.
26. Barrack RL, et al. Accuracy of acetabular component position in hip arthroplasty. *J Bone Joint Surg Am*, 2013. 95(19): p. 1760-68.
27. Frndak PA, Mallory TH, Lombardi AV. Translateral surgical approach to the hip. The abductor muscle "split". *Clin Orthop Relat Res*, 1993. 295: p. 135-41.
28. Tiberi JV, et al. A more reliable method to assess acetabular component position. *Clin Orthop Relat Res*, 2012. 470(2): p. 471-76.
29. Murray D. The definition and measurement of acetabular orientation. *J Bone Joint Surg Br*, 1993. 75-B(2): p. 228-32.
30. Woo RY, Morrey BF. Dislocations after total hip arthroplasty. *J Bone Joint Surg Am*, 1982. 64(9): p. 1295-1306.
31. Kostensalo I, et al. Effect of femoral head size on risk of revision for dislocation after total hip arthroplasty: a population-based analysis of 42,379 primary procedures from the Finnish Arthroplasty Register. *Acta Orthop*, 2013. 84(4): p. 342-47.
32. Bosker BH, et al. Poor accuracy of freehand cup positioning during total hip arthroplasty. *Arch Orthop Trauma Surg*, 2007. 127(5): p. 375-79.
33. Saxler G, et al. The accuracy of free-hand cup positioning--a CT based measurement of cup placement in 105 total hip arthroplasties. *Int Orthop*, 2004. 28(4): p. 198-201.
34. Todkar M. Obesity does not necessarily affect the accuracy of acetabular cup implantation in total hip replacement. *Acta Orthop Belg*, 2008. 74(2): p. 206-9.

35. Mouilhade F, et al. Component positioning in primary total hip replacement: a prospective comparative study of two anterolateral approaches, minimally invasive versus gluteus medius hemimytomy. *Orthop Traumatol Surg Res*, 2011. 97(1): p. 14-21.
36. Wan Z, et al. Imaging and navigation measurement of acetabular component position in THA. *Clin Orthop Relat Res*, 2009. 467(1): p. 32-42.

Chapter 3

3 Effect of Acetabular Component Positioning on Functional Levels in Primary Total Hip Arthroplasty

3.1 Introduction

Total hip arthroplasty (THA) has been previously been called the “operation of the century” given its success in addressing pain, mobility and physical function for patients suffering with osteoarthritis [1]. THA offers excellent 10-year survival of greater than 95%, and 25-year implant survival exceeding 80% [2, 3]. Technical success, however, does not necessarily translate equally to patient satisfaction especially since patients’ demands after the procedure are increasing [4]. Overall, health related quality of life outcomes after total hip arthroplasty have been largely good to excellent at short, mid- and long term follow-up [5-10]. Unfortunately, approximately 7-23% patients still suffer from persistent pain post-operatively according to a recent systemic review [11]. Poor acetabular positioning is one of the many issues implicated with persistent pain due to impingement [12-16], dislocation [17-21], edge loading [22] and liner fracture [14], which may be lead to patient dissatisfaction after a total hip arthroplasty.

One of the causes of persistent anterior groin pain is psoas impingement, which has been identified as a reason for requiring revision surgery [23, 24]. Trousdale et al. originally described two patients who had fraying of the iliopsoas tendon as a result of persistent irritation from a prominent acetabular component [23]. A metal-backed acetabular component uncovered by bone of the pelvis as a result of a retroversion or lateralization has been identified as risk factors for iliopsoas impingement [23, 25, 26]. Based on these studies, the relative position of the cup may be surmised to be of importance to patient satisfaction. However, a direct correlation between anterior overhang of the metal cup and patient satisfaction outcome has never been examined.

A number of causes leading to lateral hip pain have been described in literature. It has been proposed that lateral trochanteric pain may be associated with increased femoral offset and leg length discrepancy [27]. The effect of lateral overhang has never been implicated specifically as a cause of any post-operative complications.

Lewinnek et al. originally suggested acetabular components to be positioned in 15 ± 10 degrees of anteversion and 40 ± 10 degrees of inclination based on 9 dislocations [17]. This “safe zone” gained popularity in the literature and has since been scrutinized by many surgeons [28, 29]. There have not been any studies to our knowledge that show any effect of cup positioning within the Lewinnek’s “safe zone” on functional outcomes of patients. The ideal position of an acetabular component has only been examined as it affects tribology and stability of the hip articulation. The effect of acetabular component positioning on patient satisfaction has not been investigated.

The purpose of this study is to determine the effect of acetabular positioning in primary total hip replacements on patient satisfaction and functional outcomes at a tertiary center.

3.2 Methods

Ethics approval from our institutional research ethics board was obtained. Fellowship trained arthroplasty surgeons, with high volume practices carried out 2,829 total hip replacements between 2003 and 2011. These patients were identified with the use of our institutional arthroplasty database. Further patient demographics, including their age, sex, date of procedure, side operated on, and implant details were extracted from the database. Post-operative Western Ontario and McMaster Universities Osteoarthritis index (WOMAC), Harris hip scores (HHS) and Short Form-12 (SF-12) scores collected prospectively between two and three years from index procedure were also accumulated. WOMAC subscales were modified so a higher score (from 0-100) represented a better outcome.

A total of 1,148 hips (40.6%) were excluded based on the absence of all three functional outcome scores between two and three years from the index procedure. Only metal-on-highly crosslinked polyethylene articulations were included in our analysis. Metal-on-

metal and ceramic articulations (60 hips, 2.1%) were excluded. Further exclusions (366 hips, 13%) were based on any revision procedures, prior osteotomies, developmental hip dysplasia, inflammatory arthritis and the use of cemented acetabular components or modular neck-stem implants.

Radiographic analysis was performed by two authors (PG and AL) using prospectively collected radiographs between two and three years from the date of the procedure. Absolute position, i.e. anteversion and inclination angles were measured on anteroposterior (AP) and lateral radiographs, respectively using General Electric Centricity™ Picture Archiving and communications system (PACS). The concordance correlation coefficient was calculated to be greater than 0.9 between the two authors. Tiberi et al. showed that routine radiographs could be used to determine anteversion angle using the ischiolateral method as accurately as an edge detection software [30]. Their technique was, therefore, used by both authors to collect anteversion angles. Inclination angle was measured between the face of the acetabular component and the horizontal axis drawn by connecting the ischial tuberosities [17, 31, 32].

The relative position of the acetabular component was also measured using the same radiographs. Anterior overhang was measured on the lateral radiograph by the angle between two lines drawn from the center of the femoral head confining the exposed cup past the bony pelvis (Figure 3-1). A similar novel technique was used on the AP radiograph to measure the lateral overhang of the acetabular component (Figure 3-2). The overhang was then calculated by converting the measured angle into arc length using the following equation:

$$S = \theta / 360 * 2 \pi * (\text{cup outer diameter} / 2)$$

θ = measured angle, S = Arc length in mm (i.e. Overhang of the cup)

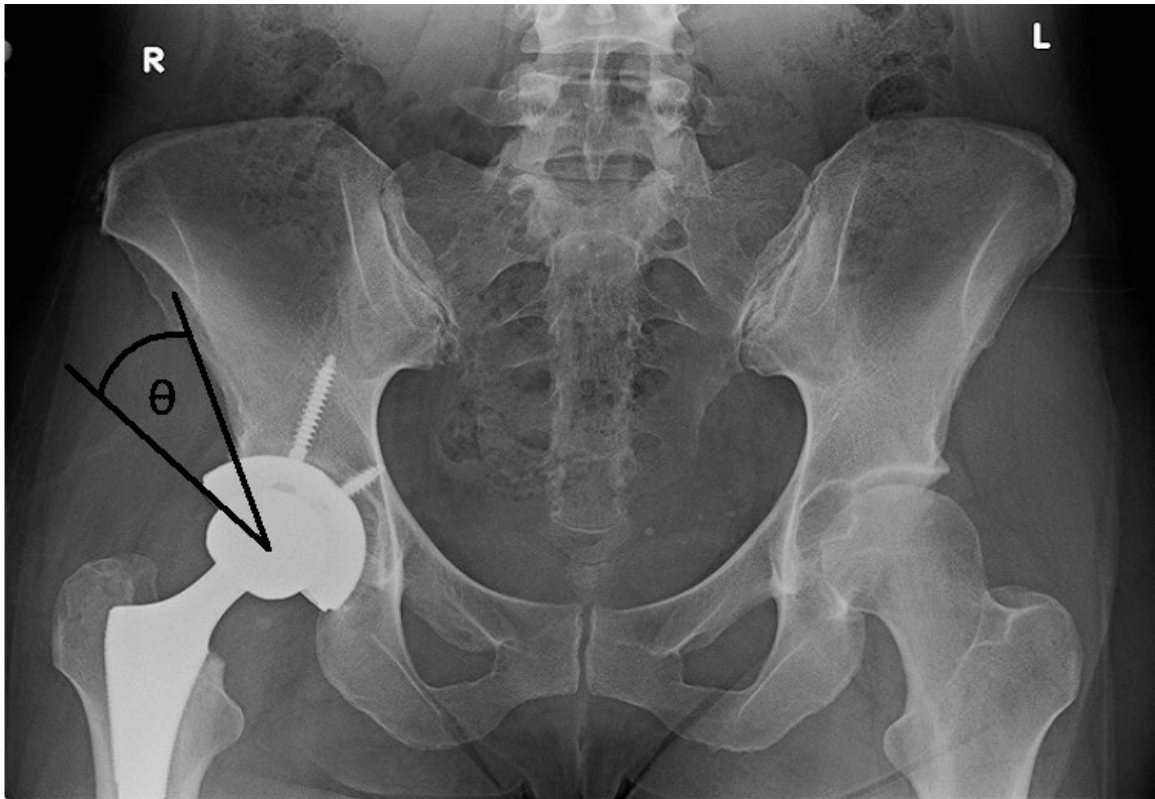


Figure 3-1: Measurement of Lateral Overhang.

An anteroposterior radiograph of the pelvis demonstrating the measurement of lateral overhang.

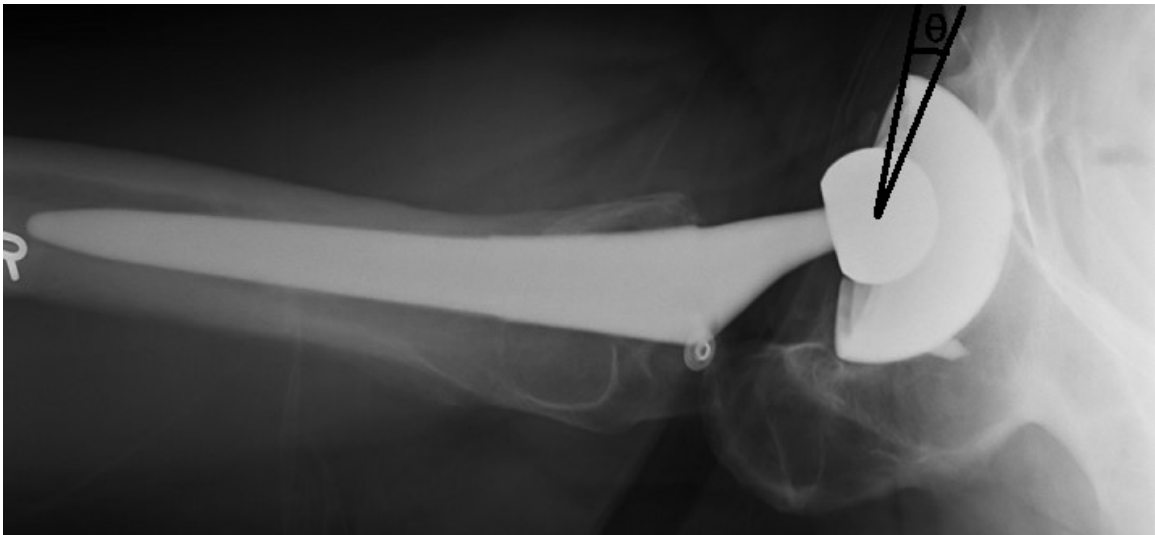

Figure 3-2: Measurement of Anterior Overhang.

A lateral radiograph demonstrating anterior overhang measurement.

The acetabular implants used in our study included Reflection™ (Smith and Nephew, Memphis, TN), Duraloc® (Depuy, Warsaw, IN), R3™ (Smith and Nephew, Memphis, TN), Pinnacle® (Depuy, Warsaw, IN) and Trident® (Stryker®, Kalamazoo, MI).

Statistical analysis was performed using SPSS® statistics version 20 (IBM®, NY). Paired t-test was used to calculate significance between pre-operative and post-operative functional outcomes scores. Spearman correlation was used to correlate functional outcomes with absolute and relative position of the acetabular component. Independent samples t-tests were carried out to determine differences between functional outcomes of patients with lateral or anterior overhang compared to those who did not. Independent samples t-test was used to ascertain differences in outcome scores between patients who had their cup positioned within the Lewinnek's "safe zone" and those who did not. A p-value of less than 0.05 was considered to be significant.

3.3 Results

The study population included 1,241 hips with 502 males (40.5%) and 739 females (59.5%). Mean BMI was 29.53 ± 6.18 kg/m². A total of 580 hips (46.7%) were left-sided and 661 (53.3%) were right-sided. The mean absolute position of the population included 21.7 ± 11.9 degrees of anteversion and 44.4 ± 6.9 degrees of inclination angle. The range of anteversion in our cohort was between -19.1 to 58.5 degrees. The range of inclination angle was 20.0 to 69.5 degrees. The relative position of the cup with respect to the pelvis demonstrated mean lateral overhang of 2.50 ± 3.39 millimeters and mean anterior overhang of 1.93 ± 3.56 millimeters. A total of 532 hips (42.9%) were within the Lewinnek's "safe zone" (Figure 3-3).

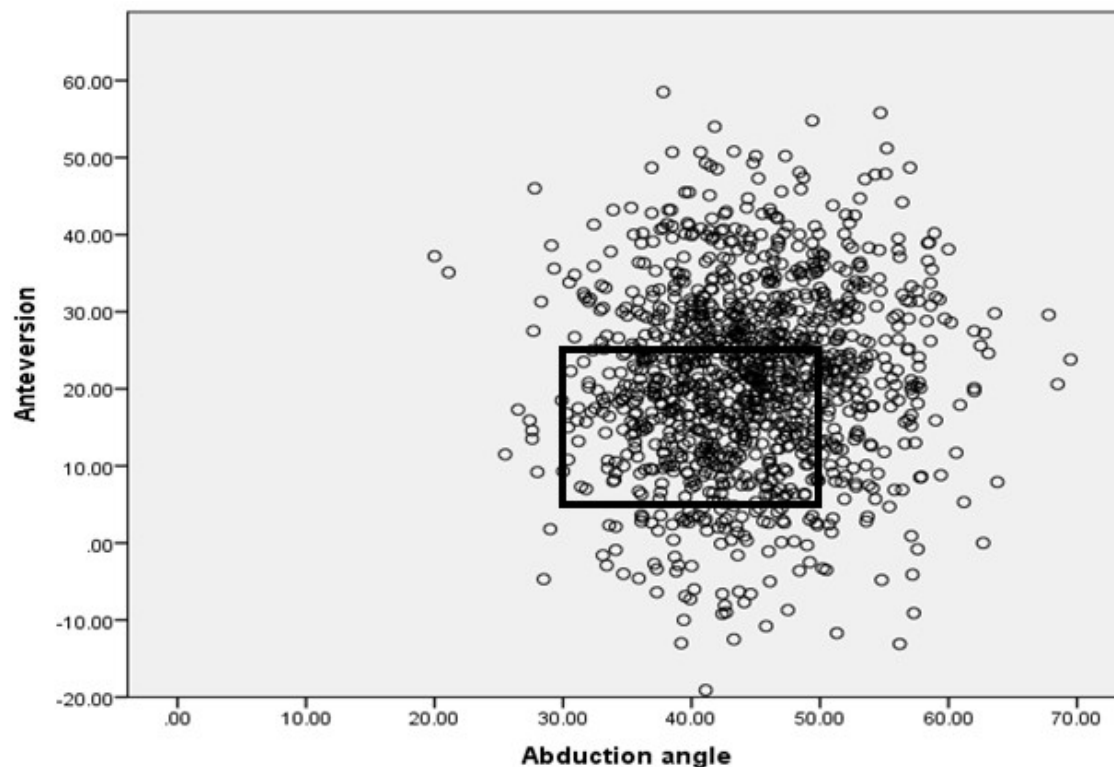


Figure 3-3: Cups within the Lewinnek's "safe zone".

Graphic representation of absolute position of the acetabular component in all patients (n=1241). Data within the rectangle represents those within the Lewinnek's "safe zone" (42.9%).

A direct comparison of pre-operative and post-operative scores in Table 3-1 demonstrates significant improvement in HHS pain, HHS function, HHS total score, and SF-12 scores ($p < 0.001$). There is significant improvement in pain, stiffness, physical function based on the WOMAC scores found in our cohort ($p < 0.001$).

Table 3-1: Functional Outcome scores showing comparison of mean pre-operative functional scores and post-operative outcome scores.

| | Pre-operative | Post-operative | p-value |
|-------------------------|----------------------|-----------------------|----------------|
| SF-12 Mental Score | 51.30 ±11.16 | 54.15 ± 9.14 | <0.001 |
| SF-12 Physical Score | 29.02 ± 7.27 | 40.63 ±11.19 | <0.001 |
| HHS pain | 18.82 ± 6.88 | 41.66 ± 5.26 | <0.001 |
| HHS function | 22.84 ± 8.06 | 39.78 ±7.66 | <0.001 |
| HHS Total Score | 46.69 ± 13.34 | 90.20 ± 10.96 | <0.001 |
| WOMAC pain | 44.52 ± 17.24 | 83.19 ± 20.25 | <0.001 |
| WOMAC stiffness | 41.65 ± 18.41 | 77.17 ± 21.32 | <0.001 |
| WOMAC physical function | 40.13 ± 17.61 | 78.95 ± 19.99 | <0.001 |
| WOMAC total | 41.34 ± 16.58 | 80.19 ± 18.68 | <0.001 |

The absolute position of the cup showed a very weak yet positive correlation in Table 3-2 between cup anteversion and HHS pain (p=0.01), HHS function (p=0.001), HHS total score (p=0.001), WOMAC pain (p=0.02), WOMAC physical function (p=0.01) and WOMAC total (p=0.02). SF-12 scores, WOMAC stiffness did not reach significance when correlated with anteversion.

Table 3-2: Correlation between functional outcome scores and anteversion.

| | Spearman Rho | p-value |
|-------------------------|---------------------|----------------|
| SF-12 Mental Score | 0.04 | 0.22 |
| SF-12 Physical Score | 0.05 | 0.12 |
| HHS pain | 0.09 | 0.01* |
| HHS function | 0.10 | 0.001* |
| HHS Total Score | 0.11 | 0.001* |
| WOMAC pain | 0.07 | 0.02* |
| WOMAC stiffness | 0.04 | 0.18 |
| WOMAC physical function | 0.08 | 0.01* |
| WOMAC total | 0.07 | 0.02* |

The absolute position of the cup did not show a significant correlation between inclination angle and any functional outcome scores as shown in Table 3-3.

Table 3-3: Correlation between functional outcome scores and inclination angle.

| | Spearman Rho | p-value |
|-------------------------|---------------------|----------------|
| SF-12 Mental Score | 0.02 | 0.52 |
| SF-12 Physical Score | 0.01 | 0.80 |
| HHS pain | 0.01 | 0.73 |
| HHS function | -0.06 | 0.08 |
| HHS Total Score | -0.04 | 0.20 |
| WOMAC pain | -0.03 | 0.32 |
| WOMAC stiffness | -0.02 | 0.41 |
| WOMAC physical function | -0.03 | 0.36 |
| WOMAC total | -0.03 | 0.28 |

The relative position of the acetabular component showed weak but negative correlation with anterior overhang of the cup and all functional outcomes shown in Table 3-4. There was a positive but weak correlation between lateral overhang of the acetabular component and HHS pain highlighted in Table 3-5 ($\rho = 0.08$, $p=0.01$). The remaining functional outcome scores and their subscales did not reach significance when they were correlated with lateral overhang.

Table 3-4: Correlation between functional outcome scores and anterior overhang.

| | Spearman Rho | p-value |
|-------------------------|---------------------|----------------|
| SF-12 Mental Score | -0.07 | 0.01* |
| SF-12 Physical Score | -0.10 | <0.001* |
| HHS pain | -0.10 | 0.002* |
| HHS function | -0.12 | <0.001* |
| HHS Total Score | -0.12 | <0.001* |
| WOMAC pain | -0.13 | <0.001* |
| WOMAC stiffness | -0.10 | <0.001* |
| WOMAC physical function | -0.14 | <0.001* |
| WOMAC total | -0.14 | <0.001* |

Table 3-5: Correlation between functional outcome scores and lateral overhang.

| | Spearman Rho | p-value |
|-------------------------|---------------------|----------------|
| SF-12 Mental Score | -0.01 | 0.74 |
| SF-12 Physical Score | -0.01 | 0.75 |
| HHS pain | 0.08 | 0.01* |
| HHS function | 0.01 | 0.83 |
| HHS Total Score | -0.02 | 0.64 |
| WOMAC pain | 0.03 | 0.59 |
| WOMAC stiffness | -0.01 | 0.81 |
| WOMAC physical function | -0.03 | 0.30 |
| WOMAC total | 0.02 | 0.58 |

Functional outcome scores between patients who had lateral uncoverage of the cup past the bony pelvis compared to patients who had full lateral bony coverage demonstrated significant differences in only HHS pain with absolute difference of less than 1 point favoring those with no lateral overhang ($p=0.02$, Table 3-6). SF-12 scores, WOMAC scores, HHS function and HHS total scores did not show significant differences between the two groups.

Table 3-6: Comparison of mean functional outcome scores between patients who have lateral overhang and patients who have no lateral overhang.

| | No Lateral Overhang | Lateral Overhang | p-value |
|-------------------------|----------------------------|-------------------------|----------------|
| SF-12 Mental Score | 54.17 ± 9.40 | 54.07 ± 8.97 | 0.84 |
| SF-12 Physical Score | 40.48 ± 11.03 | 40.58 ± 11.39 | 0.87 |
| HHS pain | 41.97 ± 5.04 | 41.20 ± 5.69 | 0.02* |
| HHS function | 39.71 ± 7.64 | 39.78 ± 7.76 | 0.89 |
| HHS Total Score | 90.56 ± 10.07 | 89.61 ± 11.58 | 0.17 |
| WOMAC pain | 83.03 ± 20.10 | 83.31 ± 20.41 | 0.81 |
| WOMAC stiffness | 77.27 ± 21.36 | 76.21 ± 22.02 | 0.40 |
| WOMAC physical function | 78.38 ± 20.19 | 79.18 ± 20.11 | 0.50 |
| WOMAC total | 80.06 ± 18.55 | 80.27 ± 18.95 | 0.85 |

A significant difference was seen in all functional outcome scores when patients with anterior overhang were compared with patients with no anterior overhang of the acetabular component (Table 3-7). The absolute differences were also very small ranging between 1 to 5 points with WOMAC, HHS and SF-12 scores favoring those without anterior overhang.

Table 3-7: Comparison of mean functional outcome scores between patients who have anterior overhang and patients who have no anterior overhang.

| | No Anterior Overhang | Anterior Overhang | p-value |
|-------------------------|-----------------------------|--------------------------|----------------|
| SF-12 Mental Score | 54.66 ± 8.83 | 52.95 ± 9.87 | 0.003* |
| SF-12 Physical Score | 41.22 ± 11.43 | 39.00 ± 10.50 | 0.001* |
| HHS pain | 41.94 ± 4.85 | 40.87 ± 6.28 | 0.002* |
| HHS function | 40.21 ± 7.51 | 38.71 ± 7.99 | 0.004* |
| HHS Total Score | 90.77 ± 10.54 | 88.65 ± 11.23 | 0.004* |
| WOMAC pain | 84.65 ± 19.78 | 79.95 ± 20.84 | <0.001* |
| WOMAC stiffness | 78.29 ± 21.15 | 73.51 ± 22.43 | <0.001* |
| WOMAC physical function | 80.35 ± 19.91 | 75.29 ± 20.26 | <0.001* |
| WOMAC total | 81.67 ± 18.27 | 76.89 ± 19.29 | <0.001* |

There was no difference in function between patients who had their acetabular component within the Lewinnek's "safe zone" when compared to patients who had the cup beyond the "safe zone" as shown in Table 3-8.

Table 3-8: Comparison of mean functional outcome scores between patients who had the cup within the Lewinnek's "safe zone" and outside the Lewinnek's "safe zone".

| | Outside Lewinnek's Zone | Inside Lewinnek's Zone | p - value |
|-------------------------|--------------------------------|-------------------------------|------------------|
| SF-12 Mental Score | 53.99 ± 9.51 | 54.30 ± 8.79 | 0.57 |
| SF-12 Physical Score | 40.59 ± 11.26 | 40.44 ± 11.11 | 0.82 |
| HHS pain | 41.54 ± 5.52 | 41.70 ± 5.14 | 0.64 |
| HHS function | 39.73 ± 7.83 | 39.76 ± 7.52 | 0.95 |
| HHS Total Score | 90.19 ± 10.96 | 90.03 ± 10.61 | 0.82 |
| WOMAC pain | 83.19 ± 20.11 | 83.13 ± 20.41 | 0.96 |
| WOMAC stiffness | 76.61 ± 22.03 | 77.01 ± 21.19 | 0.76 |
| WOMAC physical function | 78.73 ± 20.15 | 78.78 ± 20.16 | 0.96 |
| WOMAC total | 80.13 ± 18.77 | 80.19 ± 18.68 | 0.96 |

3.4 Discussion

Outcome measurements are important to clinical research as they allow us to evaluate the effectiveness of our interventions [33]. Their use in improving quality of care cannot be understated as functional outcome measures allow us to judge outcomes from a patient perspective [34]. Generic outcome measures such as SF-12, provide insight into patients' general health status including physical symptoms, function, and emotional dimensions

of health. They may not, however, be sensitive in their ability to detect small but important changes [34]. Disease-specific instruments such as WOMAC and HHS allow focused and comprehensive assessment of treatment effects [34]. This study analyzes all three outcome scores to allow a more extensive assessment of the effect of cup positioning in total hip arthroplasty.

It is important to note the importance of responsiveness of these outcome scoring methods [33]. Quintana et al. have shown that the minimal clinically important difference (MCID) for WOMAC is between 25.91 and 29.26 points for patients with primary total hip arthroplasty [35]. Although the MCID is not clearly defined in literature for SF-12 and HHS specifically for primary total hip arthroplasty, MCID for SF-12 has been shown to be between 4.5 and 12 for total knee arthroplasty [36] and MCID for HHS to be between 2.28 to 17.86 for revision total hip arthroplasty [37]. Based on these estimates of MCID of the outcome measures used in our study, the values attained between the two groups in this study are not clinically significant.

The effect of absolute and relative position of the acetabular component in total hip replacements on functional outcomes has not been studied in literature. The ideal position of the acetabular component is still debated in literature. The “ideal” position classically discussed in the literature are based only on rates of dislocation. Recent literature discusses the importance of component position focusing on tribology to define best position for the cup [38, 39]. Literature has not examined patient satisfaction as a primary outcome.

Within the ranges of anteversion and inclination angles observed in our cohort, we did not find strong correlations between the absolute position of the cup and patient satisfaction or functional outcomes scores. This study also shows that the Lewinnek’s “safe zone” does not have any direct effect on patient outcome scores (Table 3-8). Within the range of cup positions studied, patient satisfaction was not significantly affected. Nevertheless, precision in cup position remains important for tribology and hip stability.

Anterior groin pain has been described in literature and has been linked to iliopsoas impingement. The rate of iliopsoas impingement has been quoted to be as high as 4.3%

[26]. Furthermore, more than 12mm of exposed cup past the bony aspects of the pelvis has been described to be the most common reason for iliopsoas impingement [24-26]. The current study found no clinically meaningful correlation between anterior overhang of the cup with any functional outcome measure, even though statistical significance was observed. This study also highlights a statistically significant difference in functional outcomes between patients who have exposed cup past the bony pelvis compared to those who did not have any exposed cup.

Unlike anterior hip pain, lateral hip pain has not been linked strictly to cup position in our review of the literature. Lateral sided hip pain after total hip arthroplasty has been attributed many causes including infection, osteolysis, trochanteric insufficiency and soft tissue insufficiency [27]. Much like anterior pain arising from exposed cup past the bony pelvis, it can be expected that exposed cup laterally may also be a reason for lateral hip pain affecting patient outcome scores. The current study, however, does not show a correlation between exposed cup laterally and functional outcome scores. Patients with exposed cup laterally did not have any clinically meaningful differences in functional outcome scores compared to those patients who did not have any lateral overhang of the cup.

The inherent limitations in the responsiveness of the functional outcomes scores used in this study may affect the results of our study. The ceiling effect and responsiveness of these outcome measures may hinder the ability to measure effects of variation in absolute and relative position of the cup. Other limitations of the study include variations in THA position (affecting offset, leg length, and femoral anteversion), variation in head sizes, inaccuracies with radiographic measurements and the exclusion of patients who had revision procedures. However, this study examined patient reported satisfaction and outcomes on a large number of patients after a primary THA as dependent only on cup position.

Variation in the absolute and relative positions of the acetabular component within the studied ranges affects the patient reported satisfaction or function of a total hip arthroplasty, but the difference is not clinically significant. While specific intraoperative

targets for cup position may be important for tribology and hip stability, there may be no change in patient outcomes with defining such zones.

3.5 References

1. Learmonth ID, Young C, Rorabeck C. The operation of the century: total hip replacement. *The Lancet*, 2007. 370(9597): p. 1508-19.
2. Prime MS, Palmer J, Khan WS. The National Joint Registry of England and Wales. *Orthopedics*, 2011. 34(2): p. 107-10.
3. Kurtz S, et al. Projections of primary and revision hip and knee arthroplasty in the United States from 2005 to 2030. *J Bone Joint Surg Am*, 2007. 89(4): p. 780-5.
4. Mahomed NN, et al. The importance of patient expectations in predicting functional outcomes after total joint arthroplasty. *J Rheum*, 2002. 29(6): p. 1273-9.
5. Shan L, et al. Total hip replacement: a systematic review and meta-analysis on mid-term quality of life. *Osteoarthritis and Cartilage*, 2014. 22(3): p. 389-406.
6. Gould VC, Blom AW, Wylde V. Long-term patient-reported outcomes after total hip replacement: comparison to the general population. *Hip Int*, 2012. 22(2): p. 160-5.
7. Santic V, et al. Measuring improvement following total hip and knee arthroplasty using the SF-36 Health Survey. *Collegium antropologicum*, 2012. 36(1): p. 207-12.
8. Lavernia CJ, Alcerro JC. Quality of life and cost-effectiveness 1 year after total hip arthroplasty. *J Arthroplasty*, 2011. 26(5): p. 705-9.
9. Montin L, et al. The changes in health-related quality of life and related factors during the process of total hip arthroplasty. *Intl J Nursing practice*, 2011. 17(1): p. 19-26.
10. Ethgen O, et al. Health-related quality of life in total hip and total knee arthroplasty. A qualitative and systematic review of the literature. *J Bone Joint Surg Am*, 2004. 86(5): p. 963-74.
11. Beswick AD, et al. What proportion of patients report long-term pain after total hip or knee replacement for osteoarthritis? A systematic review of prospective studies in unselected patients. *BMJ Open*, 2012. 2(1):e000435.
12. Shon WY, et al. Impingement in Total Hip Arthroplasty: A Study of Retrieved Acetabular Components. *J Arthroplasty*, 2005. 20(4): p. 427-35.
13. Widmer KH, Zurfluh B. Compliant positioning of total hip components for optimal range of motion. *J Orthopaedic Research*, 2004. 22(4): p. 815-21.
14. Yamaguchi M, et al. The spatial location of impingement in total hip arthroplasty. *J Arthroplasty*, 2000. 15(3): p. 305-13.
15. D'Lima DD, et al. The effect of the orientation of the acetabular and femoral components on the range of motion of the hip at different head-neck ratios. *J Bone Joint Surg Am*, 2000. 82(3): p. 315-21.
16. Williams D, Royle M, Norton M. Metal-on-Metal Hip Resurfacing: The Effect of Cup Position and Component Size on Range of Motion to Impingement. *J Arthroplasty*, 2009. 24(1): p. 144-51.
17. Lewinnek GE, et al. Dislocations after total hip-replacement arthroplasties. *J Bone Joint Surg Am*, 1978. 60(2): p. 217-20.
18. Ali Khan M, Brakenbury P, Reynolds I. Dislocation following total hip replacement. *J Bone Joint Surg Br*, 1981. 63-B(2): p. 214-8.
19. McCollum DE, Gray WJ. Dislocation after total hip arthroplasty. Causes and prevention. *Clin Ortho Rel Res*, 1990. 261: p. 159-70.
20. Robinson M, et al. Effect of restoration of combined offset on stability of large head THA. *Hip Int*, 2012. 22(3): p. 248-53.

21. Jolles BM, Zangger P, Leyvraz PF. Factors predisposing to dislocation after primary total hip arthroplasty: a multivariate analysis. *J Arthroplasty*, 2002. 17(3): p. 282-8.
22. Leslie IJ, et al. High cup angle and microseparation increase the wear of hip surface replacements. *Clin Ortho Rel Res*, 2009. 467(9): p. 2259-65.
23. Trousdale RT, Cabanela ME, Berry DJ. Anterior iliopsoas impingement after total hip arthroplasty. *J Arthroplasty*, 1995. 10(4): p. 546-9.
24. Heaton K, Dorr LD. Surgical release of iliopsoas tendon for groin pain after total hip arthroplasty. *J Arthroplasty*, 2002. 17(6): p. 779-81.
25. O'Sullivan M, et al. Iliopsoas tendonitis a complication after total hip arthroplasty. *J Arthroplasty*, 2007. 22(2): p. 166-70.
26. Cyteval C, et al. Iliopsoas impingement on the acetabular component: radiologic and computed tomography findings of a rare hip prosthesis complication in eight cases. *J Computer Assisted Tomography*, 2003. 27(2): p. 183-8.
27. Iorio R, et al. Lateral Trochanteric Pain Following Primary Total Hip Arthroplasty. *J Arthroplasty*, 2006. 21(2): p. 233-6.
28. Eilander W, et al. Functional acetabular component position with supine total hip replacement. *BJJ*, 2013. 95-b(10): p. 1326-31.
29. Murphy WS, et al. Pelvic tilt is minimally changed by total hip arthroplasty. *Clin Ortho Rel Res*, 2013. 471(2): p. 417-21.
30. Tiberi JV, et al. A more reliable method to assess acetabular component position. *Clin Ortho Rel Res*, 2012. 470(2): p. 471-6.
31. Murray D. The definition and measurement of acetabular orientation. *J Bone Joint Surg Br*, 1993. 75-B(2): p. 228-32.
32. Woo RY, Morrey BF. Dislocations after total hip arthroplasty. *J Bone Joint Surg Am*, 1982. 64(9): p. 1295-306.
33. Poolman RW, et al. Outcome Instruments: Rationale for Their Use. *J Bone Joint Surg Am*, 2009. 91: p. 41-9.
34. Jackowski D, Guyatt G. A guide to health measurement. *Clin Ortho Rel Res*, 2003. 413: p. 80-9.
35. Quintana JM, et al. Responsiveness and clinically important differences for the WOMAC and SF-36 after hip joint replacement. *Osteoarthritis cartilage*, 2005. 13(12): p. 1076-83.
36. Clement ND, MacDonald D, Simpson AH. The minimal clinically important difference in the Oxford knee score and Short Form 12 score after total knee arthroplasty. *Knee surgery, sports traumatology, arthroscopy*, 2014. 22(8): p. 1933-9.
37. Shi HY, et al. Responsiveness and minimal important differences after revision total hip arthroplasty. *BMC MSK disorders*, 2010. 11: p. 261.
38. Kennedy JG, et al. Effect of acetabular component orientation on recurrent dislocation, pelvic osteolysis, polyethylene wear, and component migration. *J Arthroplasty*, 1998. 13(5): p. 530-4.
39. Wan Z, Boutary M, Dorr LD. The influence of acetabular component position on wear in total hip arthroplasty. *J Arthroplasty*, 2008. 23(1): p. 51-6.

Chapter 4

4 Effect of Acetabular Position on Polyethylene Liner Wear using a Novel Radiostereometric Analysis Technique

4.1 Introduction

Acetabular malpositioning has been associated with increased impingement [1-5], dislocation rates [6-10], edge loading [11], and liner fracture [3]. Moreover, inaccurate placement of the cup has been associated with increased polyethylene wear in some studies. A number of *in vivo* studies have shown increased inclination angle correlated with accelerated wear due to edge loading [12-17]. However, other studies have failed to show the same relationship [18-20]. In all cases, studies have only examined conventional polyethylene. The influence of cup position on polyethylene wear has been shown to be less important in highly crosslinked polyethylene *in vitro* [21, 22]. Simulator studies and finite element analysis have not shown greater wear rates with increased inclination angle even though higher contact stresses were noted using highly crosslinked polyethylene [22, 23]. These *in vitro* studies, however, have only examined this relationship using simulators with up to five million cycles. Due to the resistant wear properties of highly crosslinked polyethylene, more cycles are likely required to produce enough wear to establish a meaningful correlation between cup position and wear. To date, there have been no long term *in vivo* studies examining the correlation between cup position and polyethylene wear within highly crosslinked polyethylene. Abandoning the use of conventional polyethylene liners requires that this correlation between cup position and wear be re-examined with highly crosslinked polyethylene. Since cup position is under the direct control of the surgeon, this association may be of tremendous importance for long term survival of the implant.

The discrepancy noted among studies previously examining the relationship between cup position and polyethylene wear may be explained by the techniques used to determine polyethylene wear. Traditionally, plain post-operative radiographs at regular intervals

were used to measure polyethylene wear manually using the Livermore method [24]. The Dorr and Wan technique [25] and software packages were subsequently introduced to measure wear on digitized radiographs, including Martell's "Hip Analysis Suite" [26] and Devane's "PolyWare" [27, 28]. While these measurements have been shown to be reliable for conventional polyethylene liners, their utility may be limited with crosslinked polyethylene liners which have improved wear characteristics [29]. A more accurate method for wear measurement in all types of polyethylene is radiostereometric analysis (RSA), which is considered to be the gold standard for *in vivo* polyethylene wear measurement [30]. RSA utilizes simultaneously acquired biplanar radiographs within a calibrated environment to achieve an accuracy of approximately 55 μm for measurements of three-dimensional wear [31].

One of the fundamental tenets of radiography is to obtain orthogonal views for complete radiographic assessment of any joint. Further views of a joint are frequently acquired as needed based on the clinical requirements. Current RSA techniques, however, require specific positioning of the patient constrained by the reference cage design while obtaining simultaneous oblique radiographs of the joint. Furthermore, RSA setup requires that the calibration cage to be imaged together with the patient. A complete clinical assessment of the joint is, therefore, not possible with RSA radiographs as orthogonal views are not feasible with traditional techniques. An ideal RSA technique would allow wear measurement from any two views of a joint, while unlinking the reference cage from the patient completely. By unlinking the reference cage from the patient, we are able to use clinical radiographs for RSA measurements. This will allow complete clinical assessment of the joint, while providing accurate measurements of wear for every patient. This study uses a novel technique which obtains simultaneous orthogonal views of the hip that can be used for both clinical purposes and to measure wear using RSA. This technique has been previously been validated and has been shown to be as accurate as traditional RSA setup (Personal Communication, Dr. M. Teeter).

The objective of this paper is to discern the relationship between acetabular position and polyethylene wear using a modified RSA setup with orthogonal views of the hip. Despite the widespread use of highly crosslinked polyethylene, there is insufficient clinical data

in literature elucidating the correlation between acetabular cup position and polyethylene wear in highly crosslinked polyethylene. Therefore, this study examines this relationship in highly crosslinked polyethylene in patients with long term follow-up. Although the Lewinnek's "safe zone" may be important for reducing dislocation rates [6], we wish to study the effect of positioning the acetabular component on polyethylene wear when placed within this zone.

4.2 Methods

Ethics approval was obtained from the institutional research ethics board. The institutional arthroplasty database was used to identify patients who had a metal-on-polyethylene total hip arthroplasty performed at least 10 years ago. A total of 229 patients were identified using the database. All patients had an initial diagnosis of primary osteoarthritis.

Inclusion criteria included any highly crosslinked polyethylene metal-on-polyethylene primary total hip arthroplasty with Reflection® (Smith & Nephew Inc, Memphis, TN) acetabular component. Those who were ambulatory with an ability to climb 2-3 stairs were included. In order to optimize the quality of the radiographs required for this study, only patients with a BMI less than 40 were included.

Patients who underwent revision THA, had conventional polyethylene liners and those with cognitive impairments affecting their ability to follow instructions were excluded. Seven patients were excluded as they had conventional polyethylene and 2 patients had revision surgery. Two patients had cognitive deficit affecting their ability to participate in the study. Eighty-three patients had deceased at the time of follow-up for the study and were excluded. Fourteen patients denied consenting for the study. After making all attempts to identify deceased patients by reviewing obituaries in the area, we had 24 patients who were lost to follow-up for other reasons. Eighteen patients were not mobile enough to attend the clinic visit. Three patients had inadequate x-rays during the early phases of development of the technique.

A total of 43 hips were included for analysis of this study. Average follow-up was 12.3 ± 1.2 years. Further demographic data is shown in Table 4-1. The Synergy™ (Smith and Nephew, Memphis, TN) uncemented femoral stem was used in forty patients while one hip had the cemented version of the Synergy™ stem. The Spectron™ EF (Smith and Nephew, Memphis, TN) femoral stem was used in two hips.

Table 4-1: Demographics of the patient population

| | |
|--|------------------|
| Total number of hips | 43 |
| Average Age at time of follow-up (years) | 76.51 ± 7.59 |
| Average BMI (kg/m^2) | 27.90 ± 4.87 |
| Sex | |
| Male | 18 (41.9%) |
| Female | 25 (58.1%) |
| Side | |
| Left | 24 (55.8%) |
| Right | 19 (44.2%) |

Patients were contacted by telephone to attend a clinic appointment. Informed consent was obtained for the study. Western Ontario and McMaster Universities Arthritis Index (WOMAC), Harris Hip Score (HHS), Short Form-12 (SF-12) and University of California Los Angeles activity scores (UCLA) were collected at the time of the appointment.

A modified RSA examination setup was utilized (Figure 4-1), recreating standard anteroposterior (AP) and cross-table lateral exams in a single biplane RSA acquisition. The setup for the AP radiograph involved the x-ray source to be placed directly above the hip centered on the anterior superior iliac spine, with an x-ray cassette located beneath the patient within the table. For the lateral radiograph, the x-ray source was placed on the contralateral side of the affected hip, centered over the groin and parallel to the table. The x-ray cassette was positioned beside the patients' affected hip, 45 degrees to the longitudinal axis of the body, in line with the x-ray source. The patient's contralateral leg was flexed at the hip and knee away from the x-ray exposure in a standard fashion to obtain the cross-table lateral view. Both views were acquired simultaneously. The patient was then removed from the table and an acquisition of a biplanar RSA calibration cage (UmRSA® Calibration Cages™, RSA Biomedical, Umeå, Sweden) was taken, without

moving the x-ray source or detector locations. Tantalum beads embedded in the periphery of the cassette holders were used to link the patient images to the calibration cage images, in order to calibrate the x-ray setup and enable accurate measurements to be performed [32-35]. Three dimensional head penetration (accounting for polyethylene wear and creep) was measured using the center index method within RSA software (UmRSA Digital Measure® v2.2.1, RSA Biomedical, Umeå, Sweden) [36]. Average wear per year was calculated by dividing the total head penetration by the number of years that the prosthesis had been implanted.




Figure 4-1: RSA setup with setup to acquire AP and lateral radiographs.

RSA radiographs were used to measure anteversion and inclination angle. Inclination angle was calculated using a reference line through the ischial tuberosities and a line along the face of the acetabular cup [6, 37, 38]. Anteversion was calculated using the ischiolateral method as described by Tiberi et al [39, 40].

A post-hoc power analysis revealed that a sample size of 40 hips would be enough to show a moderate level of correlation ($r > 0.42$) using the Spearman rank correlation with a 5% significance level and power of 80%.

Statistical analysis was performed using SPSS[®] statistics version 20 (IBM[®], NY).

Inclination angle, anteversion showed non-normal distribution according to the Shapiro-Wilk test. Polyethylene wear rate, however, was normally distributed. Spearman correlation was, therefore, used to show association between the parameters of acetabular position (i.e. inclination angle and anteversion) and wear rate. Spearman correlation was used to determine the relationship between patient reported functional outcomes and wear. The t-test was used to compare wear rates between genders and to compare the wear rates between hips within the Lewinnek's "safe zone" [6] and those outside this zone. A p-value of 0.05 was considered significant.

4.3 Results

The average linear wear rate was calculated to be 0.066 ± 0.066 mm/year. The average total polyethylene wear was 0.840 ± 0.944 mm. The acetabular components had an average inclination of 44.1 ± 7.0 degrees. Average anteversion was 15.6 ± 11.1 degrees. Figure 4-2 graphically depicts the position of all cups included in the analysis.

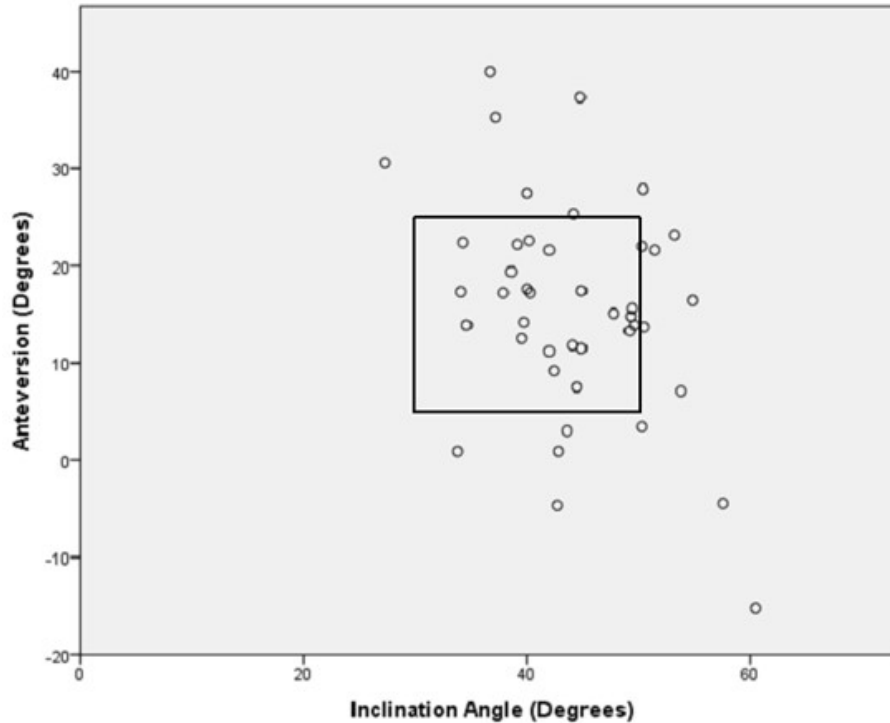


Figure 4-2: Graphic representation of the position of acetabular components. Data highlighted within the black box indicates the cups within the Lewinnek's "safe zone" (n=32).

The average polyethylene wear rate for hips within the Lewinnek's "safe zone" was 0.072 ± 0.075 mm/year. The average wear rate for hips outside this zone was 0.048 ± 0.022 mm/year. There was no significant difference between the polyethylene wear rate between the two groups ($p=0.11$).

Inclination angle was not correlated with polyethylene wear rate ($p=0.82$, Spearman rho = 0.04). Anteversion was also not correlated with polyethylene wear rate ($p=0.11$, Spearman rho = -0.25). Figure 4-3 and Figure 4-4 graphically demonstrate the position of the acetabular component with wear rate.

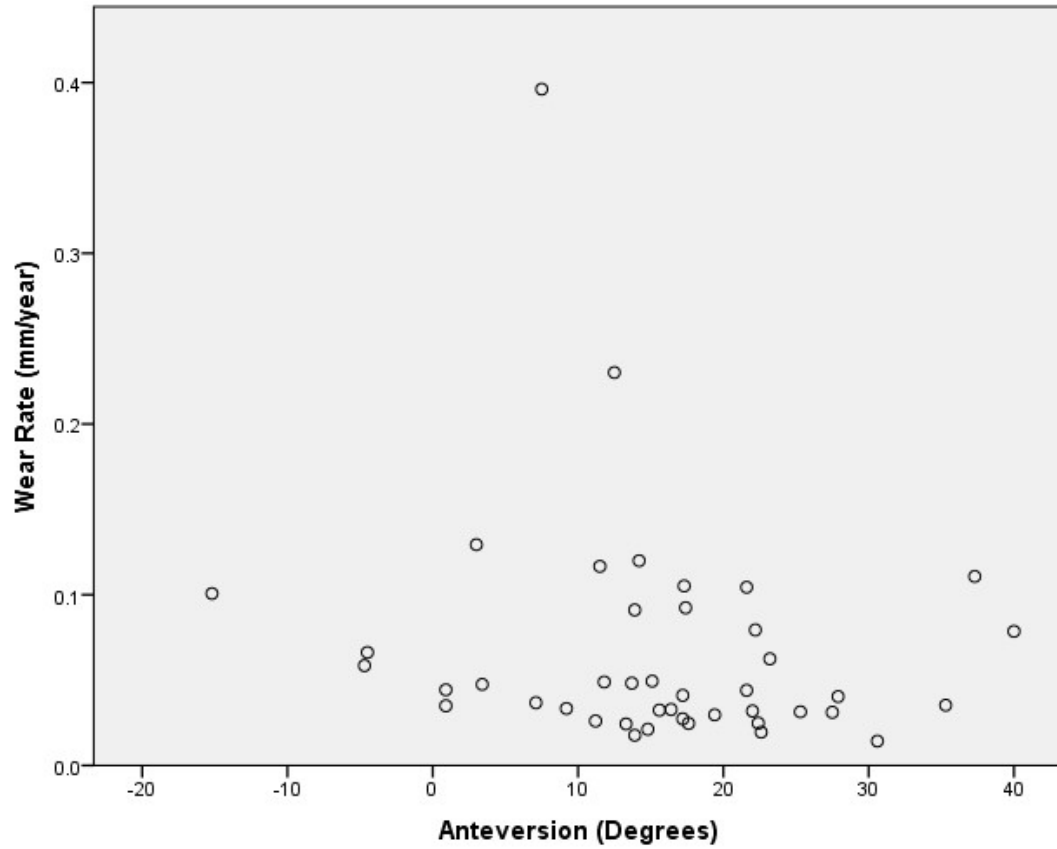


Figure 4-3: Graphic representation of the acetabular anteversion and wear rate.

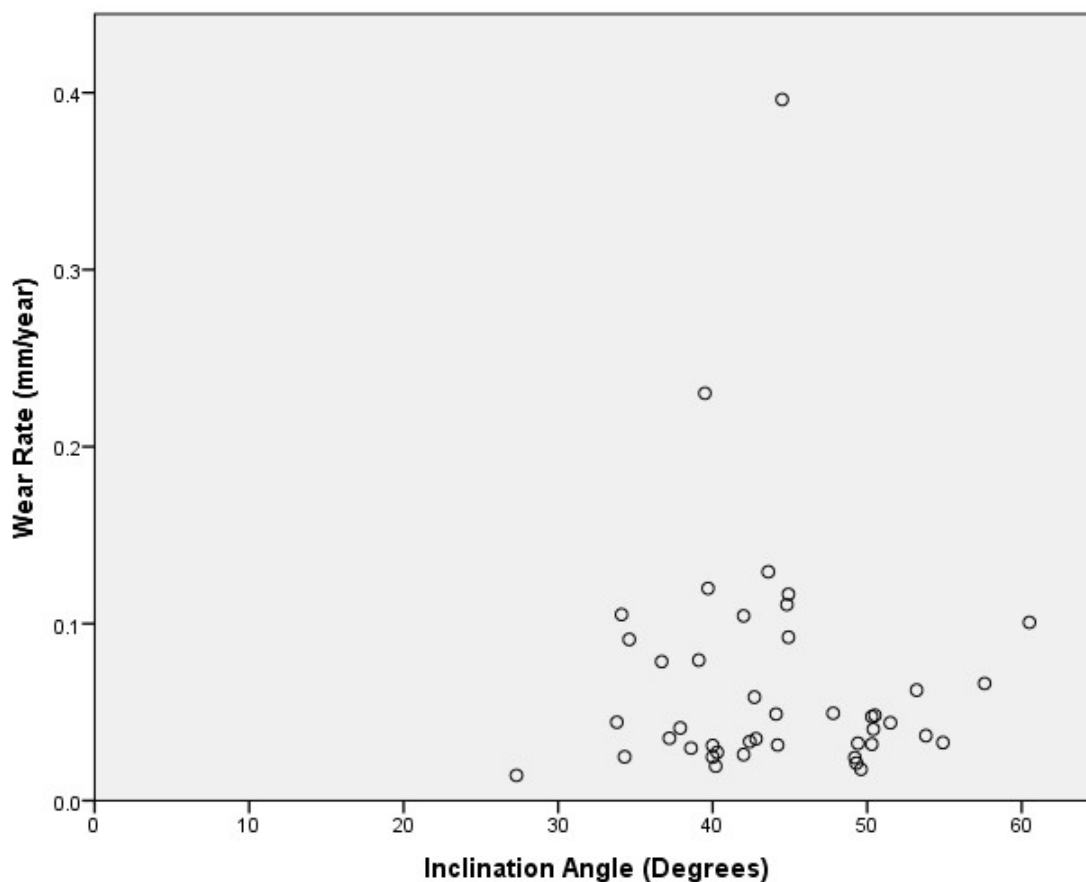


Figure 4-4: Graphic representation of the acetabular inclination angle and wear rate.

Males had a higher wear rate of 0.094 ± 0.089 mm/year compared to females with a wear rate of 0.046 ± 0.032 mm/year ($p = 0.045$). There was a significant correlation between height and polyethylene wear rate (spearman rho = 0.38, $p = 0.01$). There was no significant correlation between weight and polyethylene wear rate (spearman rho = 0.30, $p = 0.054$). Both weight and height were highly correlated with gender as males had greater weight and height ($p < 0.001$). There was no correlation between wear rate and the total implanted time of the prosthesis ($p = 0.10$).

Pre-operative and post-operative patient reported functional outcomes are summarized in Table 4-2. There was no significant correlation between polyethylene wear rate and functional outcome scores including WOMAC, SF-12, UCLA and HHS function score ($p > 0.07$). There was a weak inverse correlation between HHS pain score and polyethylene wear rate (Spearman rho = -0.34, $p = 0.047$).

Table 4-2: Mean pre-operative and post-operative patient reported functional outcome data.

| Functional Outcome Score | Pre-operative Scores | Post-operative Scores |
|--------------------------|----------------------|-----------------------|
| SF-12 | | |
| Mental Component Score | 54.46 ± 12.81 | 56.76 ± 8.85 |
| Physical Component Score | 28.14 ± 7.88 | 43.43 ± 9.66 |
| WOMAC | | |
| Pain | 42.56 ± 18.53 | 89.72 ± 20.35 |
| Stiffness | 39.10 ± 24.02 | 84.72 ± 22.40 |
| Function | 37.75 ± 18.66 | 83.33 ± 21.39 |
| Total | 40.05 ± 17.78 | 86.33 ± 20.14 |
| HHS | | |
| Pain | 17.14 ± 7.42 | 42.94 ± 1.79 |
| Function | 22.33 ± 8.80 | 38.79 ± 7.89 |
| Total | 43.53 ± 13.79 | 90.33 ± 8.08 |
| UCLA | Not collected | 5.61 ± 2.21 |

4.4 Discussion

The current study is the first to use routine hip views to measure polyethylene wear using a novel RSA technique. The current method of measuring wear through RSA technique requires oblique views of the hip largely dictated by the design of the reference cage. Unfortunately, the clinical usefulness of these views is limited. This study has shown that routine radiographic views of the hip can be used to measure polyethylene wear, avoiding additional radiation to the patient if polyethylene wear is to be measured accurately using RSA. Furthermore, the AP and lateral radiographs are taken simultaneously, which eliminates the changes in pelvic position between the two radiographs.

Moreover, this study is the first to show that no correlation exists between highly crosslinked polyethylene and cup position using accurate RSA techniques. Although, other studies have examined this relationship *in vitro*, we have demonstrated this *in vivo* with long-term follow-up. The current study did not show a general correlation between polyethylene wear and inclination angle of the acetabular component. Korduba et al. performed an *in vitro* study controlling for various factors affecting wear in highly crosslinked polyethylene including cup migration, creep and anteversion [23]. They considered cup anteversion in tandem with inclination of the cup and found that increased

cup inclination did not correlate with increased wear, which is in agreement with the finding in the current study.

A number of reports in literature have shown that increased inclination angle is associated with increased polyethylene wear [12-17]. These reports, however, have only analyzed conventional polyethylene that has poor wear properties [41]. With the advent of newer highly crosslinked polyethylene and improved tribology, the correlation between increased inclination angle and increased wear may not be the same. This is confirmed by our study as there was no correlation between inclination angle and polyethylene wear with the use of highly crosslinked polyethylene. With respect to anteversion, Patil et al. have shown that increased anteversion angles have reduced peak contact stresses using finite element analysis [12]. In the current study, anteversion was not correlated with wear. This finding is in agreement with other reports in literature [20].

Wear has previously been correlated with use but not time [42]. This study also did not find a correlation between wear rate and the total implanted time of the prosthesis. Intuitively, one would expect more polyethylene wear in patients with increased level of activity. Increased polyethylene wear has previously been correlated with increased function as determined by the use of step activity monitors [43]. The current study, however, did not show an association between patient reported functional outcomes and polyethylene wear. This finding is in accord with previous studies that have examined conventional polyethylene [43, 44]. It is likely that these scores are not sensitive enough to predict wear. The lack of correlation seen in this study may be further explained by the improved wear properties of the highly crosslinked polyethylene.

Male gender was associated with more polyethylene wear in our study. Males had two times higher wear rate compared to females. This may be explained by the increased height of the male population in our study as increased height also correlated with increased wear in this study. Furthermore, Schmalzried et al. have suggested the disparity seen between genders and polyethylene wear rates may be attributable to differences in behavior, types of activities, anatomy, physiology or a combination of these factors [42]. Height has been shown to be a risk factor for polyethylene wear in previous studies but

showed an inverse relationship unlike the current study [14]. This discrepancy is likely related to unaccounted confounding variables.

This study has limitations. Since the measurements of head penetration included both wear and creep, the yearly wear rates included in this study may be higher than the true steady state wear rate. CT is considered the gold standard for measuring cup position, but would result in significantly higher patient radiation dose [39]. We utilized the ischiolateral method, which is as accurate as the most common cup measurement method - edge detection [39]. Although only 43 patients were included in this study, there was sufficient power to show at least a moderate correlation if such a relationship existed.

This study has successfully demonstrated that routine views of the hip can be used to measure polyethylene wear using RSA. The historical correlation shown between increased inclination angle and increased polyethylene wear in conventional polyethylene was not seen in the current study, which examined highly crosslinked polyethylene. Furthermore, there was no association seen between the anteversion angle and highly crosslinked polyethylene wear. These findings may be explained by improved wear properties of highly crosslinked polyethylene. Despite the average follow-up in our study being 12 years, even longer-term follow-up is recommended to corroborate these findings between acetabular position and highly crosslinked polyethylene wear due to the projected longevity of the material.

4.5 References

1. Shon WY, et al. Impingement in Total Hip Arthroplasty: A Study of Retrieved Acetabular Components. *J Arthroplasty*, 2005. 20(4): p. 427-35.
2. Widmer KH, Zurfluh B. Compliant positioning of total hip components for optimal range of motion. *J Orthop Res*, 2004. 22(4): p. 815-21.
3. Yamaguchi M, et al. The spatial location of impingement in total hip arthroplasty. *J Arthroplasty*, 2000. 15(3): p. 305-13.
4. D'Lima DD, et al. The effect of the orientation of the acetabular and femoral components on the range of motion of the hip at different head-neck ratios. *J Bone Joint Surg Am*, 2000. 82(3): p. 315-21.
5. Williams D, Royle M, Norton M. Metal-on-Metal Hip Resurfacing: The Effect of Cup Position and Component Size on Range of Motion to Impingement. *J Arthroplasty*, 2009. 24(1): p. 144-51.
6. Lewinnek GE, et al. Dislocations after total hip-replacement arthroplasties. *J Bone Joint Surg Am*, 1978. 60(2): p. 217-20.
7. Ali Khan M, Brakenbury P, Reynolds I. Dislocation following total hip replacement. *J Bone Joint Surg Br*, 1981. 63-B(2): p. 214-18.
8. McCollum DE, Gray WJ. Dislocation after total hip arthroplasty. Causes and prevention. *Clin Orthop Relat Res*, 1990. 261: p. 159-70.
9. Robinson M, et al. Effect of restoration of combined offset on stability of large head THA. *Hip Int*, 2012. 22(3): p. 248-53.
10. Jolles BM, Zangger P, Leyvraz PF. Factors predisposing to dislocation after primary total hip arthroplasty: a multivariate analysis. *J Arthroplasty*, 2002. 17(3): p. 282-8.
11. Leslie IJ, et al. High cup angle and microseparation increase the wear of hip surface replacements. *Clin Orthop Relat Res*, 2009. 467(9): p. 2259-65.
12. Patil S, et al. Polyethylene wear and acetabular component orientation. *J Bone Joint Surg Am*, 2003. 85-A Suppl 4: p. 56-63.
13. Wan Z, Boutary M, Dorr LD. The influence of acetabular component position on wear in total hip arthroplasty. *J Arthroplasty*, 2008. 23(1): p. 51-6.
14. Gallo J, Havranek V, Zapletalova J. Risk factors for accelerated polyethylene wear and osteolysis in ABG I total hip arthroplasty. *Int Orthop*, 2010. 34(1): p. 19-26.
15. Schmalzried TP, et al. The relationship between the design, position, and articular wear of acetabular components inserted without cement and the development of pelvic osteolysis. *J Bone Joint Surg Am*, 1994. 76(5): p. 677-88.
16. Kennedy JG et al. Effect of acetabular component orientation on recurrent dislocation, pelvic osteolysis, polyethylene wear, and component migration. *J Arthroplasty*, 1998. 13(5): p. 530-4.
17. Hirakawa K, et al. Effect of acetabular cup position and orientation in cemented total hip arthroplasty. *Clin Orthop Relat Res*, 2001. 388: p. 135-42.
18. Del Schutte H, et al. Effects of acetabular abduction on cup wear rates in total hip arthroplasty. *J Arthroplasty*, 1998. 13(6): p. 621-6.
19. Kligman M, Michael H, Roffman M. The effect of abduction differences between cup and contralateral acetabular angle on polyethylene component wear. *Orthopedics*, 2002. 25(1): p. 65-7.

20. Ito M, et al. The effect of cup placement in cementless total hip arthroplasty on the wear rate of polyethylene. *Orthopedics*, 2008. 31(3): p. 225-30.
21. Halma JJ, et al. Edge loading does not increase wear rates of ceramic-on-ceramic and metal-on-polyethylene articulations. *J Biomedical Materials Research*, 2014. 102(8): p. 1627-1638.
22. Zietz C, et al. The Divergence of Wear Propagation and Stress at Steep Acetabular Cup Positions Using Ceramic Heads and Sequentially Cross-Linked Polyethylene Liners. *J Arthroplasty*, 2015. 30(8): p. 1458-63.
23. Korduba LA, et al. Effect of acetabular cup abduction angle on wear of ultrahigh-molecular-weight polyethylene in hip simulator testing. *Am J Orthop*, 2014. 43(10): p. 466-71.
24. Livermore J, Ilstrup D, Morrey B. Effect of femoral head size on wear of the polyethylene acetabular component. *J Bone Joint Surg Am*, 1990. 72(4): p. 518-28.
25. Dorr LD, Wan Z. Ten years of experience with porous acetabular components for revision surgery. *Clin Orthop Relat Res*, 1995. 319: p. 191-200.
26. Martell JM, Berdia S. Determination of polyethylene wear in total hip replacements with use of digital radiographs. *J Bone Joint Surg Am*, 1997. 79(11): p. 1635-41.
27. Devane PA, et al. Measurement of polyethylene wear in metal-backed acetabular cups. I. Three-dimensional technique. *Clin Orthop Relat Res*, 1995. 319: p. 303-16.
28. Devane PA, et al. Measurement of polyethylene wear in metal-backed acetabular cups. II. Clinical application. *Clin Orthop Relat Res*, 1995. 319: p. 317-26.
29. Mu Z, et al. A systematic review of radiological outcomes of highly cross-linked polyethylene versus conventional polyethylene in total hip arthroplasty. *Int Orthop*, 2009. 33(3): p. 599-604.
30. Callary SA, et al. Wear of highly crosslinked polyethylene acetabular components. *Acta Orthop*, 2014: p. 1-10.
31. Bragdon CR et al. Experimental assessment of precision and accuracy of radiostereometric analysis for the determination of polyethylene wear in a total hip replacement model. *J Orthop Res*, 2002. 20(4): p. 688-95.
32. Selvik G. Roentgen stereophotogrammetry. A method for the study of the kinematics of the skeletal system. *Acta Orthop Scand Suppl*, 1989. 232: p. 1-51.
33. Cai R, et al. Development of an RSA calibration system with improved accuracy and precision. *J Biomech*, 2008. 41(4): p. 907-11.
34. Borlin N, Rohrl SM, Bragdon CR. RSA wear measurements with or without markers in total hip arthroplasty. *J Biomech*, 2006. 39(9): p. 1641-50.
35. Von Schewelov T, et al. Accuracy of radiographic and radiostereometric wear measurement of different hip prostheses: an experimental study. *Acta Orthop Scand*, 2004. 75(6): p. 691-700.
36. Dahl J, et al. Center index method-an alternative for wear measurements with radiostereometry. *J Orthop Res*, 2013. 31(3): p. 480-4.
37. Murray D. The definition and measurement of acetabular orientation. *J Bone Joint Surg Br*, 1993. 75-B(2): p. 228-232.

38. Woo RY, Morrey BF. Dislocations after total hip arthroplasty. *J Bone Joint Surg Am*, 1982. 64(9): p. 1295-306.
39. Tiberi JV, et al. A more reliable method to assess acetabular component position. *Clin Orthop Relat Res*, 2012. 470(2): p. 471-6.
40. Pulos N, Tiberi JV, Schmalzried TP. Measuring acetabular component position on lateral radiographs - ischio-lateral method. *Bull NYU Hosp Jt Dis*, 2011. 69 Suppl 1: p. S84-9.
41. Digas G, et al. Highly cross-linked polyethylene in cemented THA: randomized study of 61 hips. *Clin Orthop Relat Res*, 2003. 417: p. 126-38.
42. Schmalzried TP, et al. The John Charnley Award. Wear is a function of use, not time. *Clin Orthop Relat Res*, 2000. 381: p. 36-46.
43. Takenaga RK, et al. Which functional assessments predict long-term wear after total hip arthroplasty? *Clin Orthop Relat Res*, 2013. 471(8): p. 2586-94.
44. Sechriest VF, et al. Activity level in young patients with primary total hip arthroplasty: a 5-year minimum follow-up. *J Arthroplasty*, 2007. 22(1): p. 39-47.

Chapter 5

5 Discussion

Acetabular positioning is critical to the success of a total hip arthroplasty. Cup malpositioning affects dislocation rates [1-5], edge loading [6], liner fracture [7], and can cause component impingement affecting range of motion [7-11]. Since cup position is under the control of the surgeon, it is important to study the effect of cup position to reduce such complications.

Many factors influence the surgeon's ability to accurately position the acetabular component including BMI, surgeon volume, surgeon experience and even surgical approach [12]. The modified Hardinge approach is the most common surgical approach used at our centre. Chapter 2 examined the accuracy of positioning the acetabular component using the modified Hardinge approach as it has not been elucidated in literature despite its popularity. We studied a large cohort of patients, which is comparable to previous studies that have examined the accuracy of other approaches used to perform THA [13, 14]. We found that the intended combined anteversion and inclination is only achieved in 43.6% of the cases using the modified Hardinge approach. This is comparable to the accuracy of other surgical approaches available to arthroplasty surgeons and may highlight the need for additional surgical tools to assist in cup positioning. Lastly, surgeons should be particularly mindful of acetabular position when operating on patients with a lower BMI as it was identified as a risk factor for cup malpositioning.

Even if surgeons had the ability to precisely position the acetabular component, they are faced with yet another dilemma, as the ideal position for the acetabular position is currently unknown. A number of attempts have been made in literature to define this position. Lewinnek et al. originally described a "safe zone" to reduce dislocation rates [1]. Other studies have since attempted to re-define an ideal acetabular position [3, 13, 15-18]. Unfortunately, technical perfection in accurately positioning the acetabular

component may be not necessarily translate into improved patient functional outcomes. We have examined the effect of various cup positions on patient reported functional outcomes using a large cohort. Chapter 3 has shown that the absolute cup position correlates weakly with some functional outcome scores. The relative position of the cup with respect to the bony pelvis also does not exhibit a strong effect on the functional outcome scores. Although the studied ranges of absolute and relative positions of the acetabular component affected the patient reported functional scores, the results are not clinically significant. This suggests that the surgeon may have more freedom to position the acetabular component in a wider range as long as the hip stability is maintained.

The arthroplasty literature does not clearly define the relationship between cup position and polyethylene wear. There has been conflicting data on inclination angle and its effect on polyethylene wear [19-27]. These studies have only studied conventional polyethylene *in vivo*. Despite highly crosslinked polyethylene being the more commonly used soft bearing choice, the relationship between cup position and polyethylene wear in highly crosslinked polyethylene has not been examined *in vivo*. Chapter 4 has shown that cup position does not affect wear rates even with long term follow-up of patients with highly crosslinked polyethylene. Of the patient demographics assessed, only male gender was associated with higher polyethylene wear rates compared to females. We recommend confirming these findings between acetabular position and highly crosslinked polyethylene wear rates with even longer term follow-up studies due to the anticipated longevity of the newer polyethylene material.

Lewinnek's "safe zone" is still the most commonly cited position for the acetabular component in literature. Although the Lewinnek's "safe zone" has been shown to be important for dislocation rates [1], we found that this "safe zone" has no effect on patient reported functional outcomes. Furthermore, this "safe zone" is not correlated with polyethylene wear in highly crosslinked polyethylene. The importance of this zone, therefore, may be limited to reducing dislocation of the prosthesis. Surgeons, therefore, may have fewer constraints on the final position of the acetabular component with respect to both functional outcomes and polyethylene wear.

We have shown that functional scores used in our studies did not correlate with polyethylene wear and cup position. However, the sensitivity of these outcome scores may be the limiting factor in establishing a correlation with various parameters of THA as the ceiling effect of these scores may constrain clinical correlations of this study. Therefore, functional outcome measurements with improved resolution may be of great importance for clinical research in the future.

5.1 Future Directions

Pelvic orientation (specifically flexion and extension of the pelvis) can adversely affect the tribology of the THA as the vector for biomechanical loading is dependent on pelvic position. Mechanical guides fail to account for the change in pelvic orientation or patient anatomy when the patient is in a functional position [12]. Lumbar lordosis is lost intraoperatively with the lateral decubitus position that is most commonly used for THA [3]. Furthermore, pelvic flexion has been shown to be variable with supine, standing and sitting positions [12]. Therefore, a cup appropriately placed based on bony landmarks intraoperatively may not be in the same position in a functional standing position, which is critical for balancing hip biomechanics and forces across the hip joint. Therefore, a comparison of cup position in supine position with cup position in a functional standing position may show significant differences.

In a standing position, the femoral head is loaded with forces in excess of three times the body weight. Therefore, it can be assumed that the femoral head is maximally displaced and engaged into the acetabular component. In a supine position, however, relatively weaker forces from soft tissue tensioning and capsule may be inadequate to maintain the femoral head in the same position affecting polyethylene wear measurements [28]. Contrary to this reasoning, studies have showed no differences in wear in standing and supine radiographs [28-30]. These studies, however, have examined hips with short-term follow-up, in low-wear cohort or used techniques with low resolution for measuring wear. In contrast, a study showed positional differences in wear measurements with hips known to have radiographic polyethylene wear [31]. Hence, with the use of RSA technology, these positional differences with respect to polyethylene wear in patients

with long-term follow-up can be studied with great accuracy in THA with highly crosslinked polyethylene.

Overall, acetabular position may be important for dislocation rates. The effect of acetabular position on patient outcomes and polyethylene wear, however, is not as influential. Surgeons, therefore, may have more flexibility in positioning the acetabular component than previously believed. As current surgical approaches are only moderately accurate in acetabular positioning, the errors made during cup placement may not be devastating to the patients so long as the prosthetic hip remains stable.

5.2 References

1. Lewinnek GE, et al. Dislocations after total hip-replacement arthroplasties. *J Bone Joint Surg Am*, 1978. 60(2): p. 217-20.
2. Ali Khan, M, Brakenbury P, Reynolds I. Dislocation following total hip replacement. *J Bone Joint Surg Br*, 1981. 63-B(2): p. 214-18.
3. McCollum DE, Gray WJ. Dislocation after total hip arthroplasty. Causes and prevention. *Clin Orthop Relat Res*, 1990(261): p. 159-70.
4. Robinson M, et al. Effect of restoration of combined offset on stability of large head THA. *Hip Int*, 2012. 22(3): p. 248-53.
5. Jolles BM, Zangger P, Leyvraz PF. Factors predisposing to dislocation after primary total hip arthroplasty: a multivariate analysis. *J Arthroplasty*, 2002. 17(3): p. 282-8.
6. Leslie IJ, et al. High cup angle and microseparation increase the wear of hip surface replacements. *Clin Orthop Relat Res*, 2009. 467(9): p. 2259-65.
7. Yamaguchi M, et al. The spatial location of impingement in total hip arthroplasty. *J Arthroplasty*, 2000. 15(3): p. 305-13.
8. Shon WY, et al. Impingement in Total Hip Arthroplasty: A Study of Retrieved Acetabular Components. *J Arthroplasty*, 2005. 20(4): p. 427-35.
9. Widmer KH, Zurfluh B. Compliant positioning of total hip components for optimal range of motion. *J Orthop Res*, 2004. 22(4): p. 815-21.
10. D'Lima DD, et al. The effect of the orientation of the acetabular and femoral components on the range of motion of the hip at different head-neck ratios. *J Bone Joint Surg Am*, 2000. 82(3): p. 315-21.
11. Williams D, Royle M, Norton M. Metal-on-Metal Hip Resurfacing: The Effect of Cup Position and Component Size on Range of Motion to Impingement. *J Arthroplasty*, 2009. 24(1): p. 144-151.
12. Daines BK, Dennis DA. The importance of acetabular component position in total hip arthroplasty. *Orthop Clin North Am*, 2012. 43(5): p. e23-34.
13. Barrack RL, et al. Accuracy of acetabular component position in hip arthroplasty. *J Bone Joint Surg Am*, 2013. 95(19): p. 1760-8.
14. Callanan MC, et al. The John Charnley Award: risk factors for cup malpositioning: quality improvement through a joint registry at a tertiary hospital. *Clin Orthop Relat Res*, 2011. 469(2): p. 319-29.
15. Dorr LD, et al. Classification and treatment of dislocations of total hip arthroplasty. *Clin Orthop Relat Res*, 1983(173): p. 151-8.
16. Biedermann R, et al. Reducing the risk of dislocation after total hip arthroplasty: the effect of orientation of the acetabular component. *J Bone Joint Surg Br*, 2005. 87(6): p. 762-9.
17. Elkins JM, Callaghan JJ, Brown TD. The 2014 Frank Stinchfield Award: The 'landing zone' for wear and stability in total hip arthroplasty is smaller than we thought: a computational analysis. *Clin Orthop Relat Res*, 2015. 473(2): p. 441-52.
18. Grammatopoulos G, et al. The effect of orientation of the acetabular component on outcome following total hip arthroplasty with small diameter hard-on-soft bearings. *Bone Joint J*, 2015. 97-b(2): p. 164-72.

19. Patil S, et al. Polyethylene wear and acetabular component orientation. *J Bone Joint Surg Am*, 2003. 85-A Suppl 4: p. 56-63.
20. Wan Z, Boutary M, Dorr LD. The influence of acetabular component position on wear in total hip arthroplasty. *J Arthroplasty*, 2008. 23(1): p. 51-6.
21. Gallo J, Havranek V, Zapletalova J. Risk factors for accelerated polyethylene wear and osteolysis in ABG I total hip arthroplasty. *Int Orthop*, 2010. 34(1): p. 19-26.
22. Schmalzried TP, et al. The relationship between the design, position, and articular wear of acetabular components inserted without cement and the development of pelvic osteolysis. *J Bone Joint Surg Am*, 1994. 76(5): p. 677-88.
23. Kennedy JG, et al. Effect of acetabular component orientation on recurrent dislocation, pelvic osteolysis, polyethylene wear, and component migration. *J Arthroplasty*, 1998. 13(5): p. 530-4.
24. Hirakawa K, et al. Effect of acetabular cup position and orientation in cemented total hip arthroplasty. *Clin Orthop Relat Res*, 2001. 388: p. 135-42.
25. Del Schutte H, et al. Effects of acetabular abduction on cup wear rates in total hip arthroplasty. *J Arthroplasty*, 1998. 13(6): p. 621-6.
26. Kligman M, Michael H, Roffman M. The effect of abduction differences between cup and contralateral acetabular angle on polyethylene component wear. *Orthopedics*, 2002. 25(1): p. 65-7.
27. Ito M, et al. The effect of cup placement in cementless total hip arthroplasty on the wear rate of polyethylene. *Orthopedics*, 2008. 31(3): p. 225-30.
28. Moore KD, et al. The effect of weight-bearing on the radiographic measurement of the position of the femoral head after total hip arthroplasty. *J Bone Joint Surg Am*, 2000. 82(1): p. 62-9.
29. Bragdon CR, et al. Standing versus supine radiographs in RSA evaluation of femoral head penetration. *Clin Orthop Relat Res*, 2006. 448: p. 46-51.
30. Martell JM, Leopold SS, Liu X. The effect of joint loading on acetabular wear measurement in total hip arthroplasty. *J Arthroplasty*, 2000. 15(4): p. 512-8.
31. Smith PN, Ling RS, Taylor R. The influence of weight-bearing on the measurement of polyethylene wear in THA. *J Bone Joint Surg Br*, 1999. 81(2): p. 259-65.

Appendix A: University of California Los Angeles Activity Score

| | |
|----------------------------|--|
| UCLA Activity Score | Hip ID: _____ |
| | Study Hip: <input type="checkbox"/> Left <input type="checkbox"/> Right |
| | Examination Date (MM/DD/YY): / / |
| Interval: _____ | |

| |
|---|
| Check one box that best describes current activity level. |
| <p><input type="checkbox"/> 1: Wholly Inactive, dependent on others, and can not leave residence</p> <p><input type="checkbox"/> 2: Mostly Inactive or restricted to minimum activities of daily living</p> <p><input type="checkbox"/> 3: Sometimes participates in mild activities, such as walking, limited housework and limited shopping</p> <p><input type="checkbox"/> 4: Regularly Participates in mild activities</p> <p><input type="checkbox"/> 5: Sometimes participates in moderate activities such as swimming or could do unlimited housework or shopping</p> <p><input type="checkbox"/> 6: Regularly participates in moderate activities</p> <p><input type="checkbox"/> 7: Regularly participates in active events such as bicycling</p> <p><input type="checkbox"/> 8: Regularly participates in active events, such as golf or bowling</p> <p><input type="checkbox"/> 9: Sometimes participates in impact sports such as jogging, tennis, skiing, acrobatics, ballet, heavy labor or backpacking</p> <p><input type="checkbox"/> 10: Regularly participates in impact sports</p> |

Appendix B: Ethics Approval



Research Ethics

Western University Health Science Research Ethics Board HSREB Delegated Initial Approval Notice

Principal Investigator: Dr. Brent Lanting

Department & Institution: Schulich School of Medicine and Dentistry/Orthopaedic Surgery, London Health Sciences Centre

HSREB File Number: 106404

Study Title: Effect of acetabular position on functional outcomes of patients with primary total hip arthroplasty

Sponsor:

HSREB Initial Approval Date: March 23, 2015

HSREB Expiry Date: March 23, 2016

Documents Approved and/or Received for Information:

| Document Name | Comments | Version Date |
|---------------------------------------|-----------------------|--------------|
| Data Collection Form/Case Report Form | Data Collection Sheet | 2015/02/19 |
| Western University Protocol | Received Feb.19/15 | |

The Western University Health Science Research Ethics Board (HSREB) has reviewed and approved the above named study, as of the HSREB Initial Approval Date noted above.

HSREB approval for this study remains valid until the HSREB Expiry Date noted above, conditional to timely submission and acceptance of HSREB Continuing Ethics Review.

The Western University HSREB operates in compliance with the Tri-Council Policy Statement Ethical Conduct for Research Involving Humans (TCPS2), the International Conference on Harmonization of Technical Requirements for Registration of Pharmaceuticals for Human Use Guideline for Good Clinical Practice Practices (ICH E6 R1), the Ontario Personal Health Information Protection Act (PHIPA, 2004), Part 4 of the Natural Health Product Regulations, Health Canada Medical Device Regulations and Part C, Division 5, of the Food and Drug Regulations of Health Canada.

Members of the HSREB who are named as Investigators in research studies do not participate in discussions related to, nor vote on such studies when they are presented to the REB.

The HSREB is registered with the U.S. Department of Health & Human Services under the IRB registration number IRB 00000940.

This is an official document. Please retain the original in your files.



**Western
Research**

**Western University Health Science Research Ethics Board
HSREB Full Board Initial Approval Notice**

Research Ethics

Principal Investigator: Dr. Brent Lanting

Department & Institution: Schulich School of Medicine and Dentistry/Orthopaedic Surgery, London Health Sciences Centre

HSREB File Number: 105507

Study Title: Effects of acetabular component position on polyethylene wear in total hip arthroplasty.

Sponsor:

HSREB Initial Approval Date: November 06, 2014

HSREB Expiry Date: June 30, 2017

Documents Approved and/or Received for Information:

| Document Name | Comments | Version Date |
|---------------------------------|------------------------------|--------------|
| Western University Protocol | | 2014/09/30 |
| Letter of Information & Consent | | 2014/09/30 |
| Recruitment Items | Letter to Accompany LOI | 2014/10/06 |
| Instruments | Survey Tool- WOMAC | |
| Instruments | Survey Tool-SF12 | |
| Instruments | Survey Tool-Harris Hip Score | |
| Instruments | UCLA Activity Score | |

The Western University Health Science Research Ethics Board (HSREB) has reviewed and approved the above named study, as of the HSREB Initial Approval Date noted above.

HSREB approval for this study remains valid until the HSREB Expiry Date noted above, conditional to timely submission and acceptance of HSREB Continuing Ethics Review. If an Updated Approval Notice is required prior to the HSREB Expiry Date, the Principal Investigator is responsible for completing and submitting an HSREB Updated Approval Form in a timely fashion.

The Western University HSREB operates in compliance with the Tri-Council Policy Statement Ethical Conduct for Research Involving Humans (TCPS2), the International Conference on Harmonization of Technical Requirements for Registration of Pharmaceuticals for Human Use Guideline for Good Clinical Practice Practices (ICH E6 R1), the Ontario Personal Health Information Protection Act (PHIPA, 2004), Part 4 of the Natural Health Product Regulations, Health Canada Medical Device Regulations and Part C, Division 5, of the Food and Drug Regulations of Health Canada.

Members of the HSREB who are named as Investigators in research studies do not participate in discussions related to, nor vote on such studies when they are presented to the REB.

The HSREB is registered with the U.S. Department of Health & Human Services under the IRB registration number IRB 0000940.

This is an official document. Please retain the original in your files.

Appendix C: Letter of Information and Consent Form



Effects of acetabular component position on polyethylene wear in metal-on-polyethylene total hip arthroplasty in a functional position.

Study Doctors

Study Coordinator

Primary Investigator

Dr. Brent Lanting

Mrs. Abby Korczak

Co-Investigators

Dr. James Howard

Dr. Matthew Teeter

Resident

Dr. Prateek Goyal

Dear Patient:

You are being invited to voluntarily participate in a research study designed to study the amount of wear in total hip replacement. This letter of information describes the research study and your role as the participant. Please read this form carefully. Do not hesitate to ask anything about the information provided. Your doctor or nurse will describe the study and answer your questions.

Study Purpose

Although total hip replacements have been extremely successful, their survivorship has been limited by problems related to wear of the plastic liners that are used in the cup portion of the hip replacement. We would like to study if positioning the cup in different

positions has an effect on liner wear. We are also studying whether wear on the liner can be better detected using x-rays that have been taken in a standing or a lying position.

Procedure

If you decide to participate in this study you will be required to schedule a follow-up visit with your orthopaedic surgeon. The standard of care for routine follow-up visits requires that patients have two x-rays taken of their hip prior to their visit with their surgeon. Participants in this study will not have these x-rays taken. Instead, you will meet a member of the study team in the lobby of the orthopaedic outpatient clinic prior to your visit with your surgeon. This individual will escort you to the Robarts Research Center, a short five minute walk from the orthopedic outpatient clinic. A wheelchair will be provided for you if needed. Here your hip will be x-rayed using a special type of x-ray called radiostereometric analysis (RSA). This x-ray will help us to determine how much wear is on the plastic liner of your hip replacement. RSA x-rays will be taken of your hip while you are in a standing and lying position. These RSA x-rays will be assessed by your surgeon in the same manner your standard x-rays are examined. . These one-time RSA x-rays will take approximately 15 minutes to complete. After the RSA x-ray is complete, you will be escorted back to the orthopaedic outpatient clinic and your visit will continue as per standard of care. Prior to seeing your surgeon, we will ask you to fill out three surveys that include questions that will help us to determine how well your hip replacement is functioning. These questions are standard of care for all joint replacement patients regardless of study participation.

Inclusion and Exclusion Study Criteria

Study participants will be eligible to participate in the study if:

1. They have a reflection cup and a cross-linked or conventional type of plastic liner;
2. It has been at least 10 years since they had their surgery completed.

Individuals will not be eligible to participate in this study if:

1. The head component of their hip replacement is made of ceramic or oxinium;

2. They have had revision surgery;
3. They are unable to walk or fully dependent on a wheelchair for mobility;
4. Have a body mass index greater than 40;
5. Are pregnant;
6. It has been less than 10 years since their surgery was completed.

Potential Study Risks

There is always a slight chance of cancer from excessive exposure to radiation. Special care is taken during x-ray examinations to use the lowest radiation dose possible while producing the best images for evaluation.

The scientific unit of measurement for radiation dose is the millisevert (mSv). People are exposed to radiation from natural sources all the time. The average person receives an effective dose of about 3-5 mSv per year from naturally occurring radioactive materials and cosmic radiation from outer space.

The two RSA examinations of the hip in this study will expose the patient to 0.300 mSv of ionizing radiation, or 10% of the background radiation we are all exposed to yearly (which is 3-5 mSv). In comparison, the standard follow-up x-rays that are being replaced by these RSA examinations would have exposed the patient to 0.280 mSv of ionizing radiation, or 9% of yearly background radiation.

In the event of a study related injury, care will be provided to you at no cost.

Potential Benefits Associated with this Study

You may or may not benefit directly from participation in this study. Potential benefits of joining this study may include the ability for the surgeon to make a more accurate assessment of implant performance. The outcomes of this study may help increase the understanding of the impact of liner manufacturing process on hip replacement liner wear and patient outcome scores. This in turn, in the future, could help modify or enhance the care and treatment of other patients with osteoarthritis in the hip.

There is no guarantee of benefit by participating in this study.

Voluntary Participation

Participation in the study is voluntary. You may refuse to participate, refuse to answer any questions or withdraw from the study at any time with no effect on your future care. Any new information obtained during the course of the research that may affect your willingness to continue participation in the study will be provided to you. You do not waive any legal right by signing the consent form.

Alternatives to Study Participation

If you choose not to participate, you will continue to be followed by your surgeon as per standard of care for all orthopaedic joint replacement patients.

Compensation

No compensation will be given for study participation.

Confidentiality

You will not be identified personally in any publication or communication resulting from this study. All information collected will be stored in a locked office and entered into a secure hospital computer on a server accessible by authorized individuals only. This information will be used solely for this research study. The data collected from the RSA x-ray will be processed at the Robarts Research Institute, a secure research facility. This data will be stored on password-protected computer, and will be made anonymous by coding it with a numeric identifier. Only research staff working on this project will have access to this data. Information collected for this study will be kept for a period of five years. Health information collected as part of this study will be kept confidential unless release is required by law. You have the right to request the withdrawal of your information at any time. A copy of this letter will be given to you. Representatives of the University of Western Ontario Health Sciences Research Ethics Board may require

access to your study-related records or follow-up with you to monitor the conduct of this research.

Questions

If you have any questions about your rights as a research participant or the conduct of the study you may contact Dr. David Hill, Scientific Director, c/o Lawson Health Research Institute.

If you have any questions about this study or your care please contact Dr. Brent Lanting, primary study investigator and orthopaedic surgeon at London Health Sciences Centre-University Hospital, or Abby Korczak, study coordinator.

Consent Form

Agreement of Participant

I have read the letter of information, have had the nature of the study explained to me, and I agree to participate. All questions have been answered to my satisfaction.

Print Participant's full name

Participant's signature

Name of person obtaining consent

Signature of person obtaining consent

I would like to be contacted again in the future for possible participation in another research study.

Yes

No

Appendix D: Permissions for Copyrighted Material

Dear Dr Goyal

Thank you for your inquiry. Please find our permission statement below. This permission relates exclusively to this request:

Hardinge K. The direct lateral approach to the hip. *J Bone Joint Surg [Br]* 1982;64-B:17-19. (Figures 2,3,4,5,6)

Thank you for your permission request. We are pleased to grant permission for you to reproduce figures 2 through to 6, incl., from the aforementioned article, provided full and correct acknowledgement of source is given. On this occasion the permission is granted free of charge as permission is for inclusion in your thesis and therefore falls under the category of academic purposes, and is not for widespread or commercial publication or distribution, but please note that our fees are usually £110 per page or £55 per table or figure, meaning that this request would ordinarily be charged at £275 GBP. In the event that your thesis is widely published please let us know as there may be a charge involved.

Our standard acknowledgement is as follows below (please ensure you cite the paper as shown above):

"Reproduced with permission and copyright. © of the British Editorial Society of Bone and Joint Surgery [citation]."

Please note that as a courtesy it is necessary to seek, or make all reasonable attempts to seek, the author's permission in each case. The most recent address can be found on the title page of the article. I have managed to find two email addresses for K.Hardinge: [redacted] (spelt without e at the end of surname so this may be a typo - suggest you try also with an e) and [redacted]

if you have any further questions, please do not hesitate to contact me.

Kind regards,

Curriculum Vitae

PRATEEK GOYAL**Post-secondary Education and Degrees**

- **Postgraduate Education in Orthopaedic Surgery**, Post-graduate year 4, Department of Surgery, Western University (2012 – present)
- **Master of Science (Surgery)** candidate, Western University (2013 – present)
- **Doctor of Medicine (M.D.)**, University of Ottawa (2008-2012)
- **Bachelor of Sciences – Honours Biology (BSc H)** (2003-2007)

Honours and Awards

- Runner up for Best clinical paper at Residents' Research Day 2014
- Dr. James H. Roth award for best poster at Residents' Research Day 2013
- Ira Krupen Memorial Scholarship for contribution to Cardiology 2011
- Deryck Stone Scholarship for contribution to Cardiology research 2011
- Award for Excellence in Collaboration in PBL/CBL 2009
- Dr. Robert & Shirley Cross Scholarship for academic excellence 2009
- Dean's Honor List - McMaster University 2003-2007
- Stephen F. H. Threlkeld award for leadership and innovative skills 2006
- Woodstock Hall Residence Scholarship for highest overall GPA 2006
- Dr. Harry Lyman Hooker Scholarship for overall academic excellence 2006
- McMaster Honour Entrance award 2003

Research Grants

- Department of Surgery Resident Research Grant (\$5000) 2014

Related Work Experience

- Research Assistant – Dr. Neil Fam (University of Toronto) Summer 2009
 Laboratory Technician – Dr. Derek Van Der Kooy (University of Toronto) 2007-2008
 Research Assistant – Dr. Bhagwati Gupta (McMaster University) Summer 2006

Publications:

- **Mentored Simulation Training Improves Procedural Skills in Cardiac Catheterization: A Randomized, Controlled Pilot Study.** Circ Cardiovasc Interv. 2012;5:672-679
- **Novel Gold Nanoshell Based Diagnostic and Therapeutic Technology for Future Cancer Treatment.** McMaster University Medical Journal 2007;4(1):48-52.